

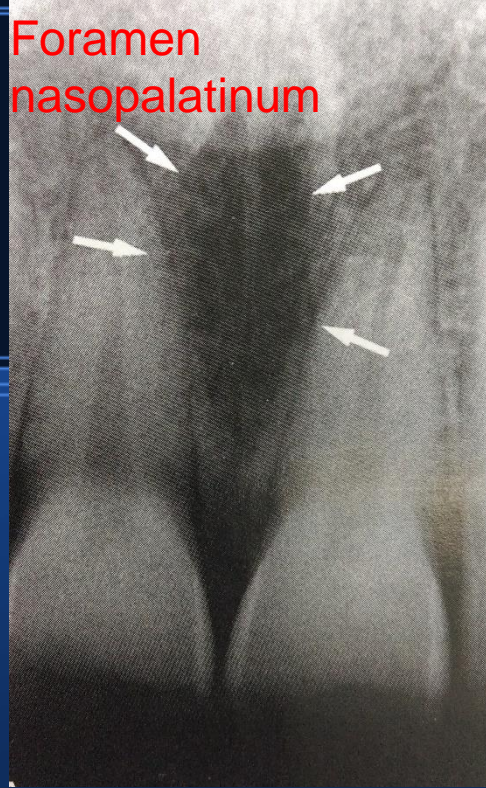Diferencijalna dijagnoza prozračnosti čeljusti

Josip Biočić

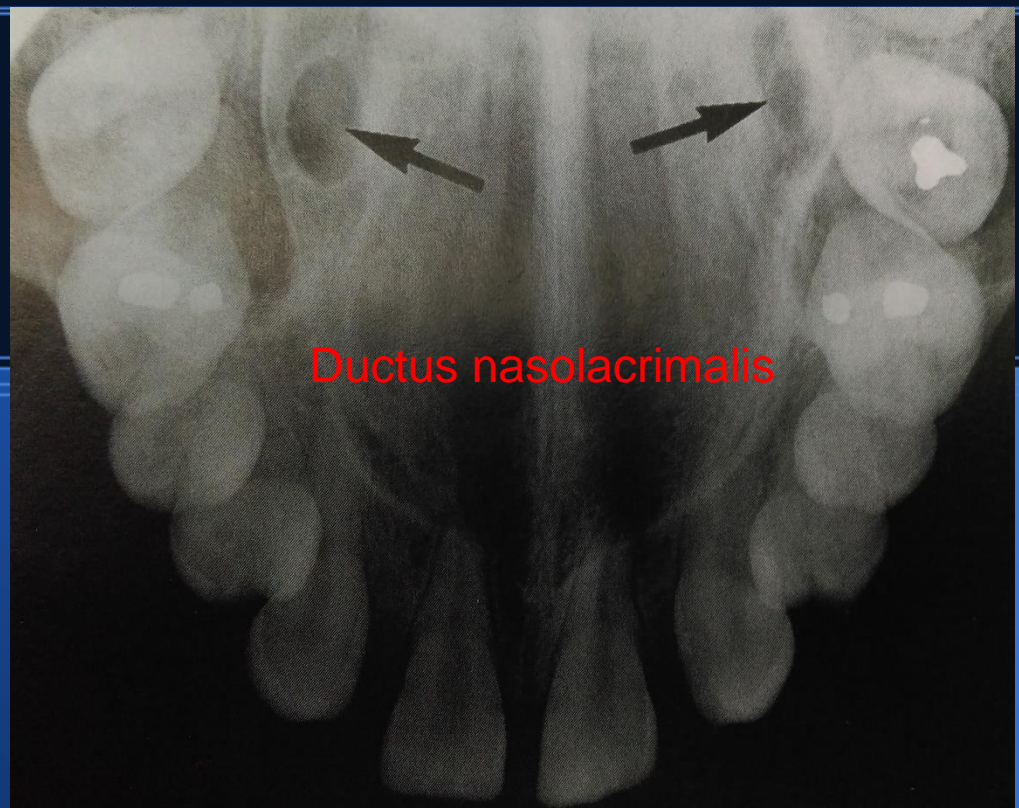
Zavod za oralnu kirurgiju
Stomatološkog fakulteta
Sveučilišta u Zagrebu

- Poznavanje normalne anatomije na radiološkim nalazima
- Fiziološke varijacije struktura
- Analiza i orijentacija na cijeli prikaz, a ne samo da zonu interesa
- **Usporedba s kliničkim nalazom!**

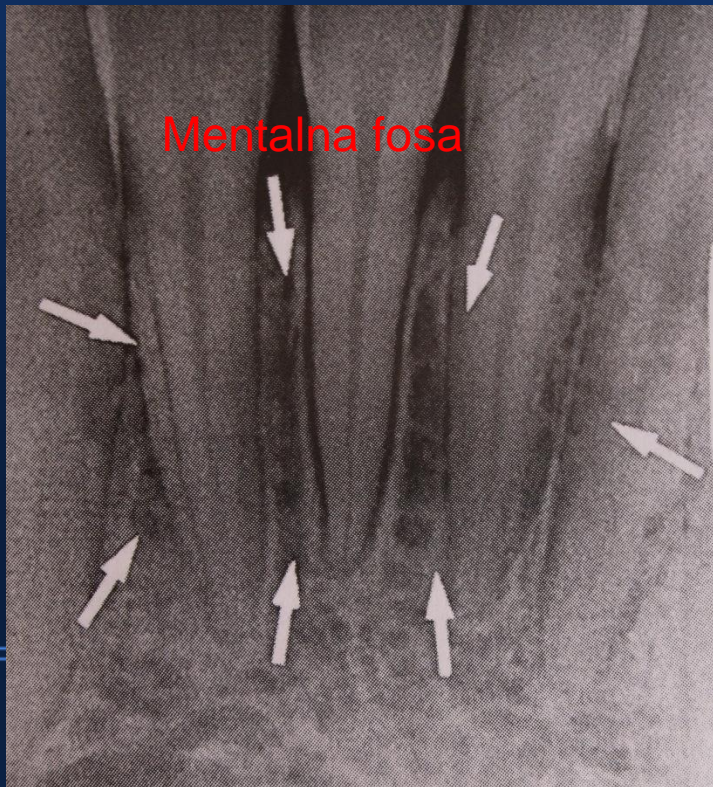
Foramen
nasopalatinum



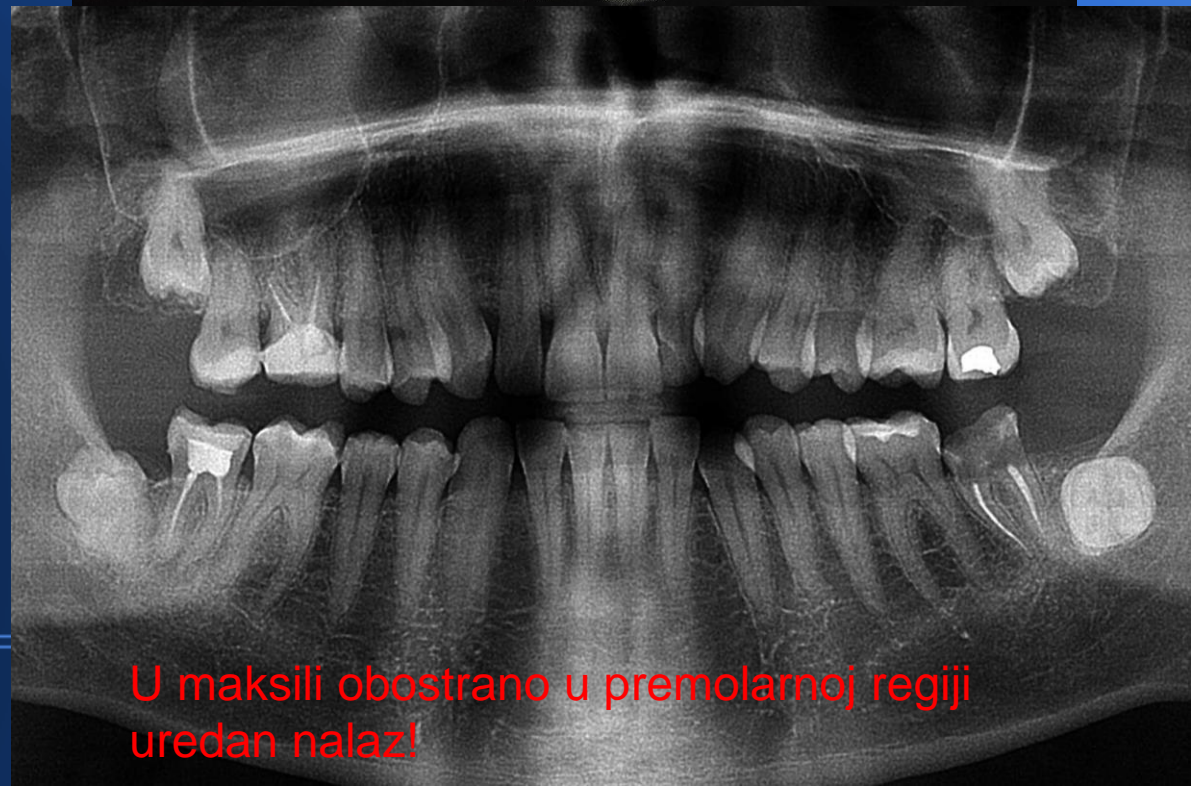Ductus nasolacrimalis



Mentalna fosa



U maksili obostrano u premolarnoj regiji
uredan nalaz!



Osnove analize

- Lokalizacija
- Oblik i granice
- Analiza interne strukture
- Analiza utjecaja lezije na okolne strukture

Lokalizacija

- Lokalizirana (unilateralna ili bilateralna)
- Generalizirana

Lokalizacija

- Iznad ili ispod mandibularnog kanala
- U samom kanalu-projekcija (vaskularna ili neuralna etiologija)
- Odnos prema kruni/korijenu zuba (resorpcija, pomicanje, folikularna cista, adenomatoidni odontogeni tumor)
- Antrum maksilarnog sinusa
- Artikularni nastavak

Oblik i granica


- Dobro ili slabo ograničena promjena (kronični ostitički proces-difuzni ili jasno ograničen, karcinom vs benigni)
- Kortikalni ili sklerotični rub (ciste, cementne displazije)
- "punched-out" rub (multipli mijelom, histiocitoza)
- Difuzni sklerozirani "rub" (sklerozirani osteitis)
- Difuzne nepravilne granice (maligni tumor)
- Oblik (okrugao, valovit...)

Interna struktura

- Potpuna prozračnost
- Djelomična prozračnost sa sjenama (kalcifikacijama)
- Potpuna zasjenjenost

Od prozračnosti do zasjenjenja

- Zrak, masno tkivo, plin
- Tekućina
- Meka tkiva
- Koštana srž
- Trabekularna kost
- Kortikalna kost i dentin (cement)
- Čaklina
- Metal

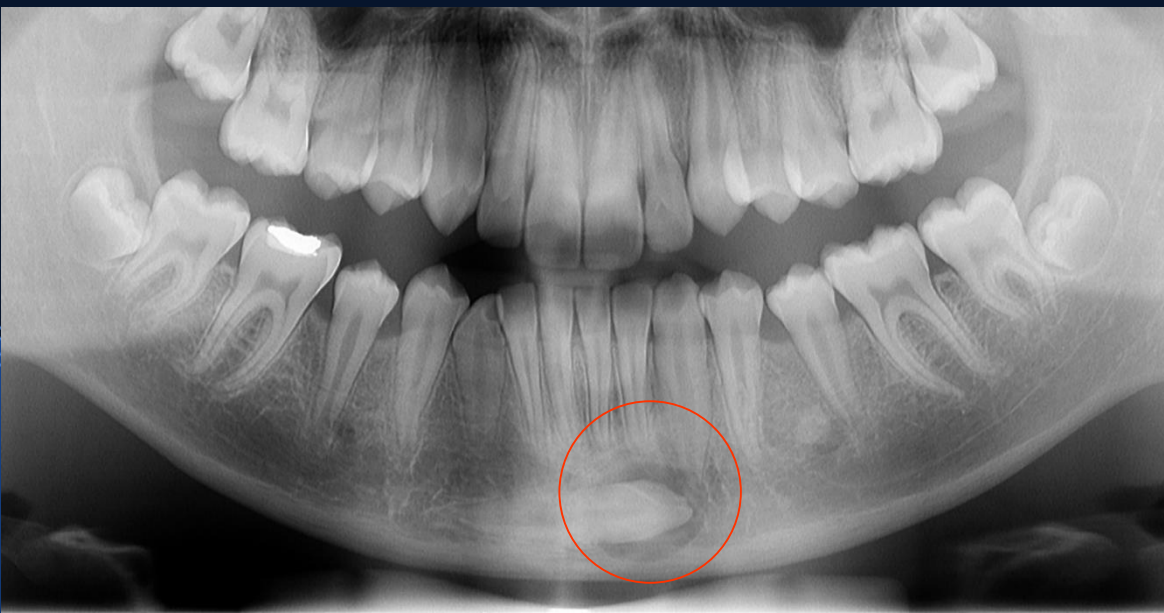


Utjecaj lezije na okolne strukture

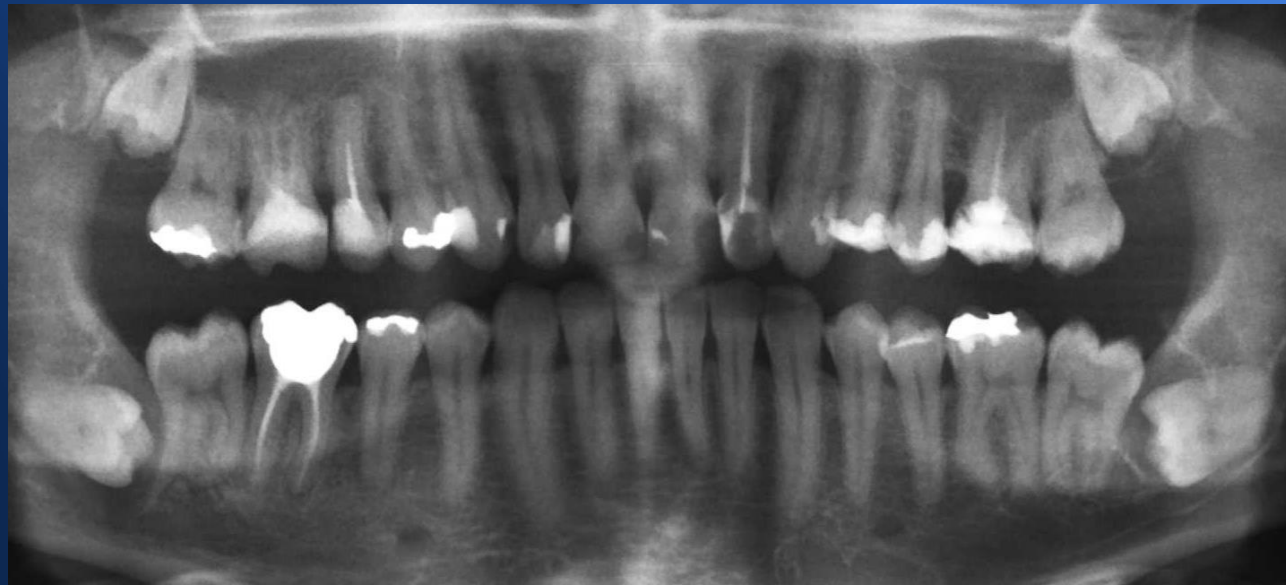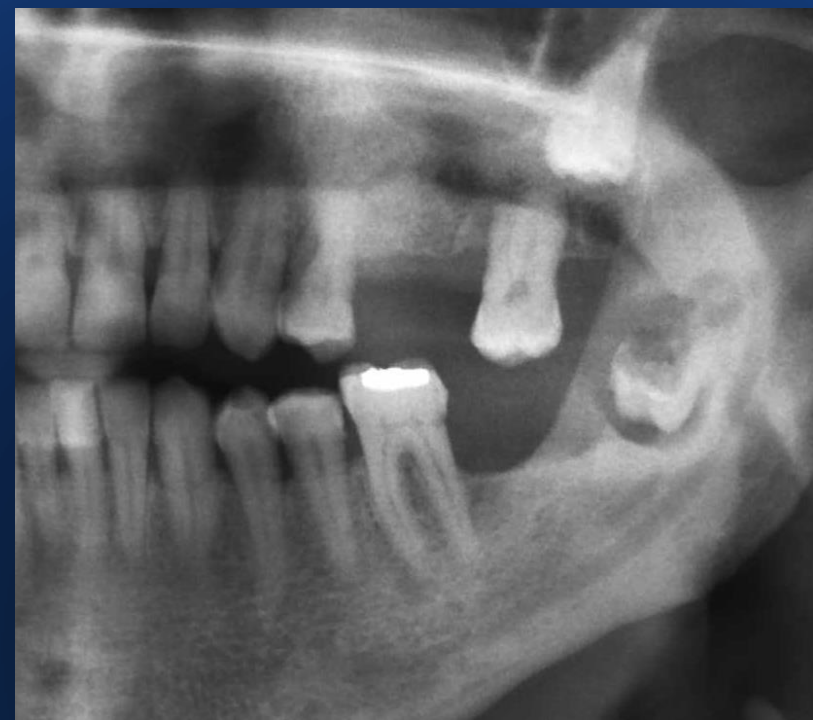- Procjena ponašanja promjene
- Razmicanje i potiskivanje zubi (odontomi, kerubizam...)
- Resorpcija zubi (amleoblastom, osificirajući fibrom, centralni gigantocelularni granulom)
- Poticanje stvaranja okolne reaktivne kosti
- Alveolarni kanal
- Subperiostalno stvaranje nove kosti (poput luka ili poput spikula)

Unilokularno perikoronarno prosvjetljenje

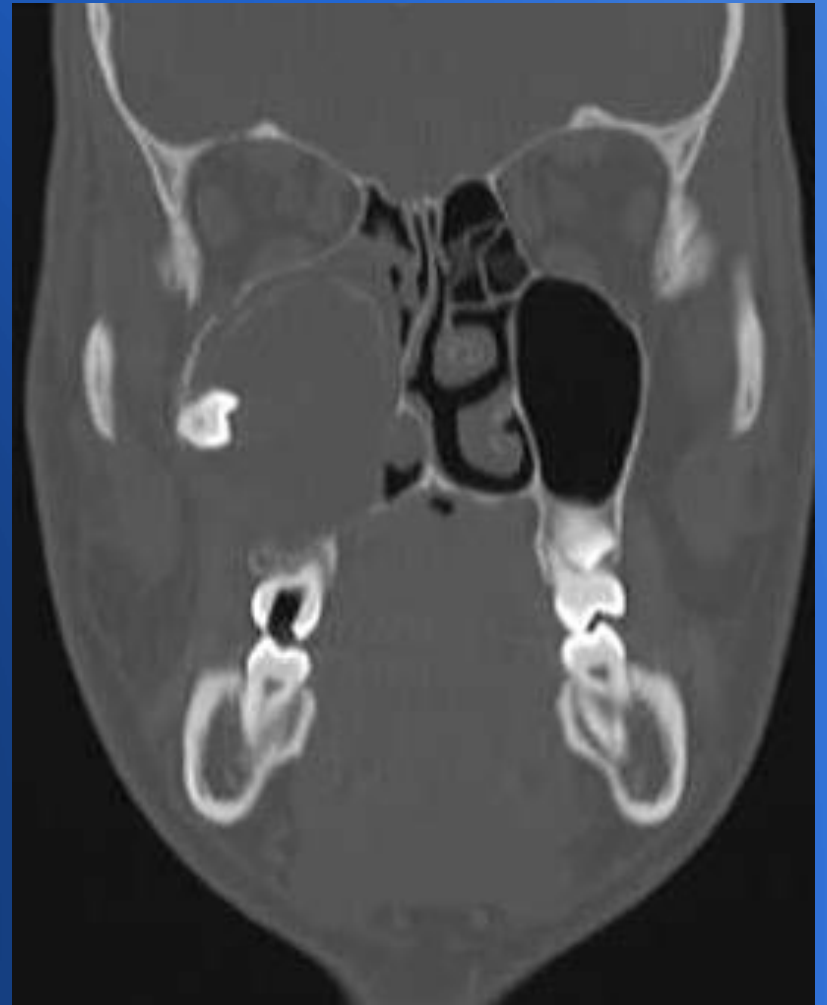
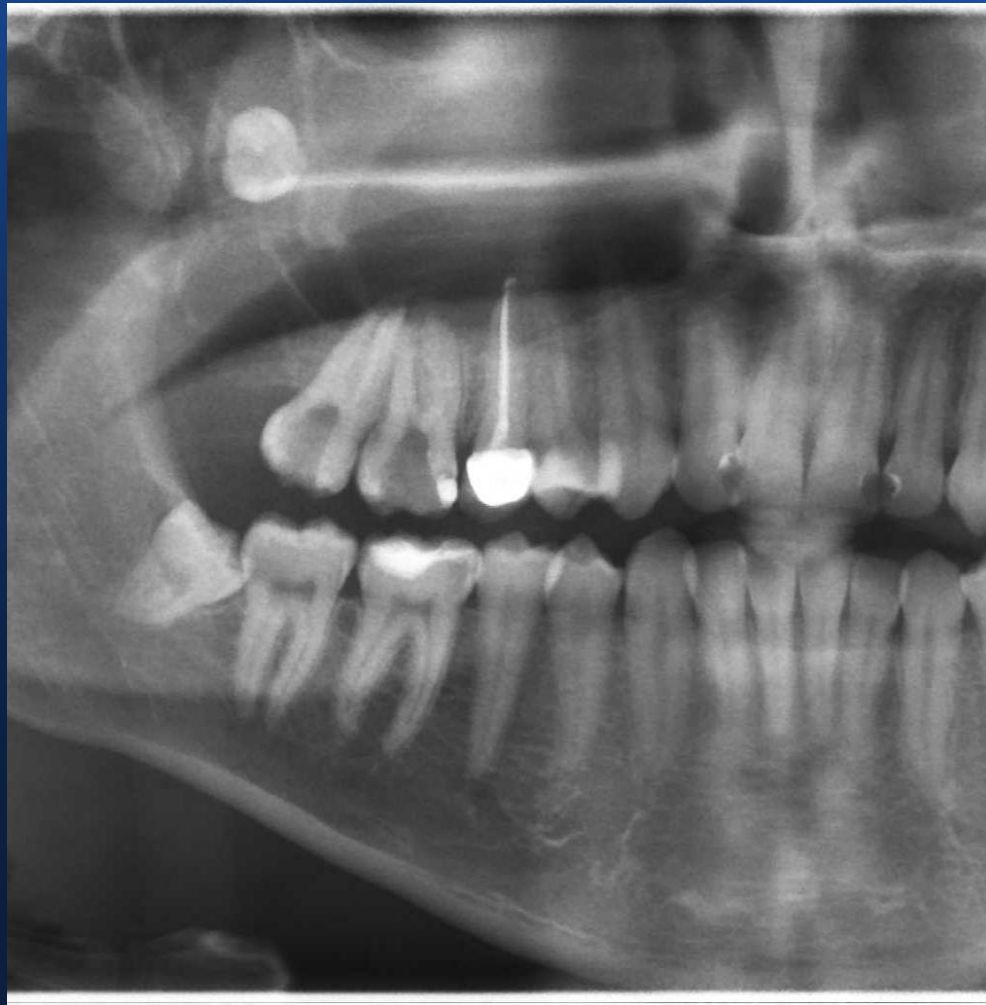- Dentalni folikul (do 3-5 mm)
- Folikularna cista (preko 3-5 mm)
- Eruptivna cista
- Keratocistični odontogeni tumor/keratocista
- Ameloblastom
- Adenomatoidni odontogeni tumor



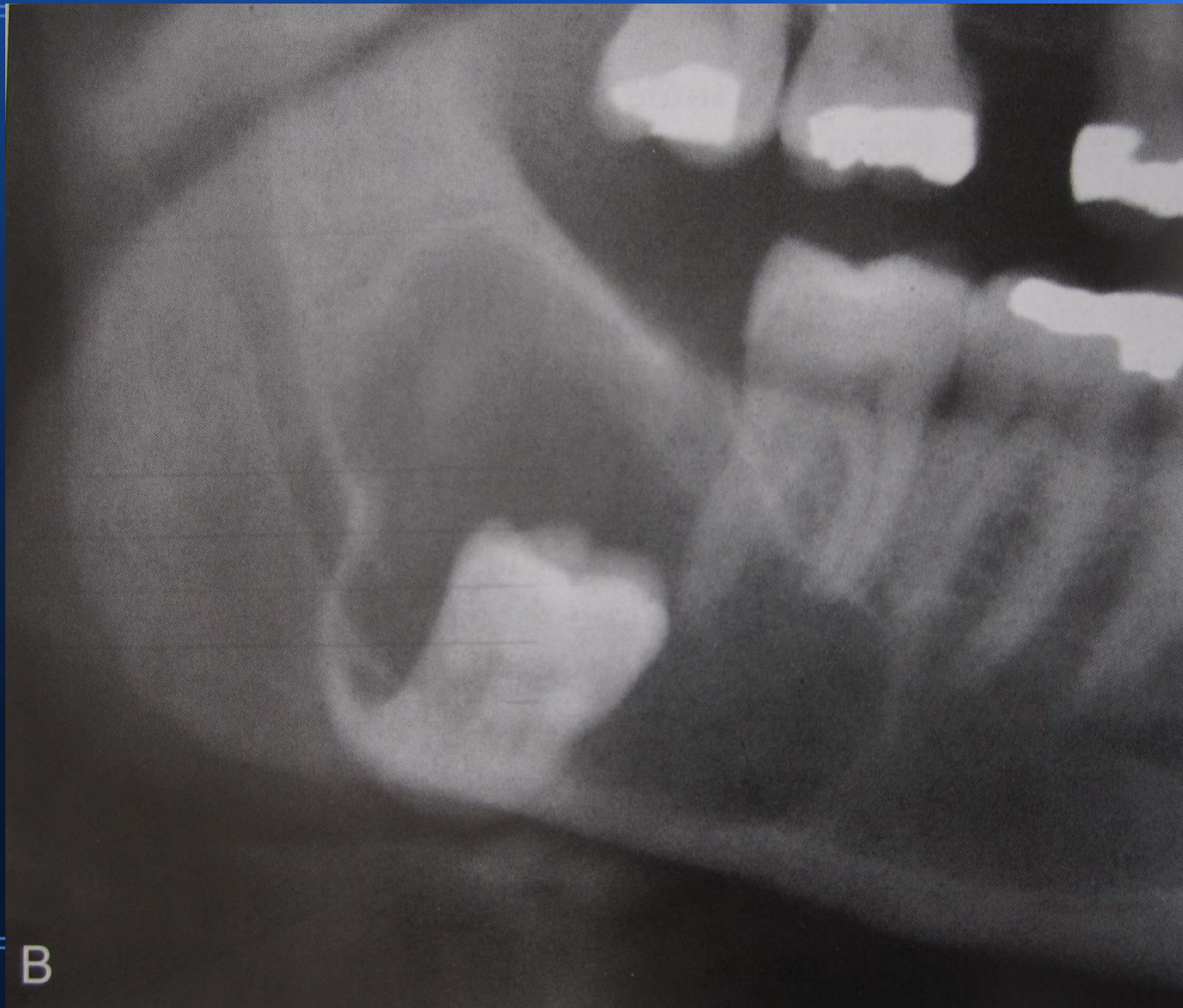
Folikul ili folikularna cista
počinje od caklinskocementnog
spojišta!



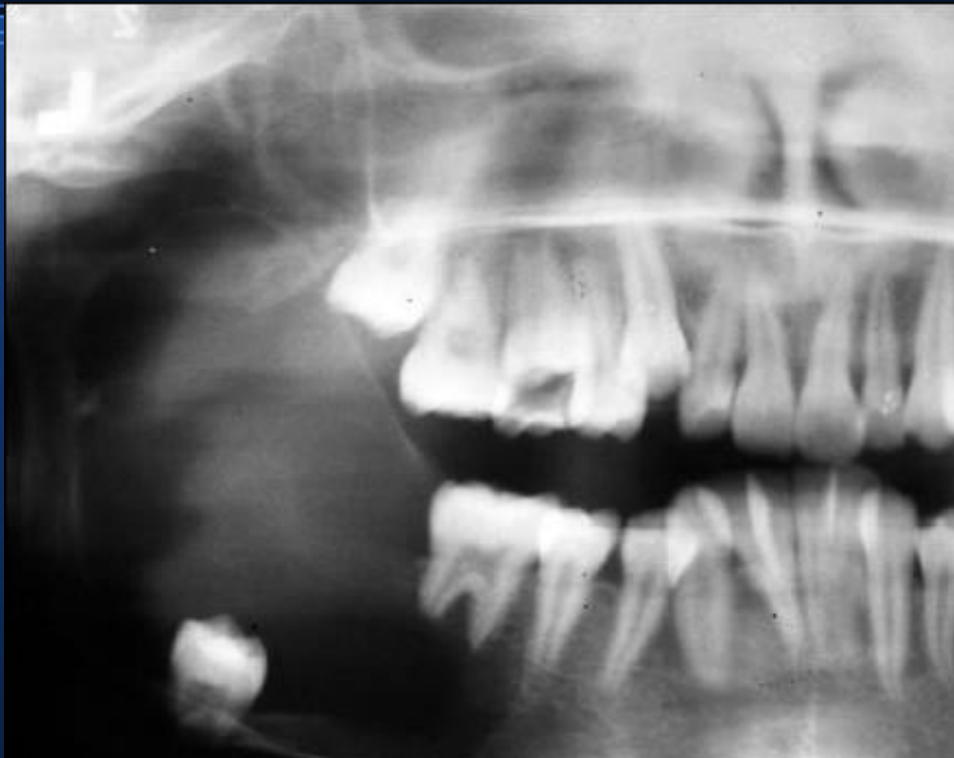Keratocista



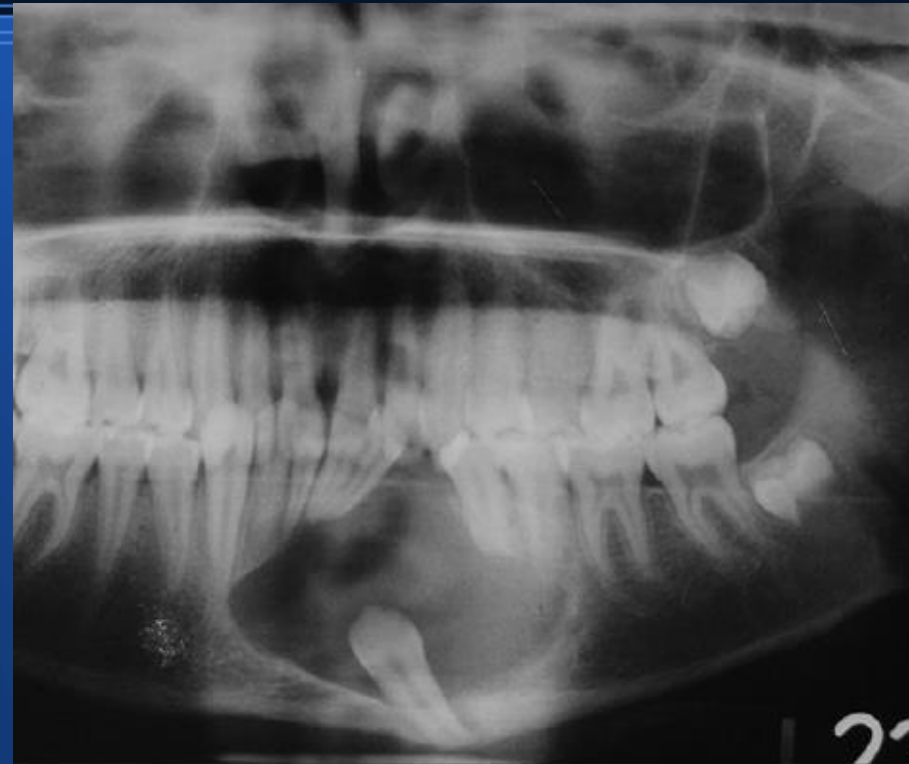
Keratocista (karakteristični valoviti rub,
distalna regija mandibule i hvatište drugačije od
folikularne ciste)



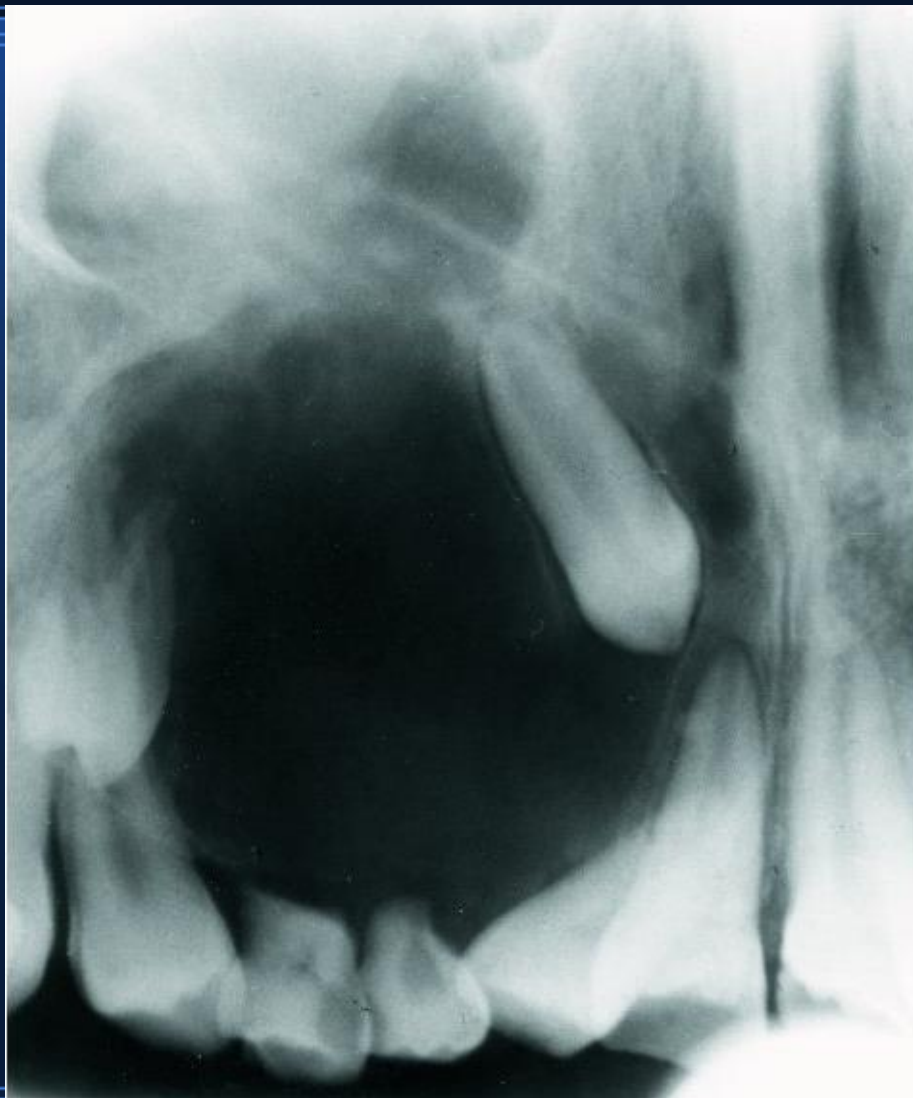Ameloblastom



Adenomatoidni odontogeni tumor



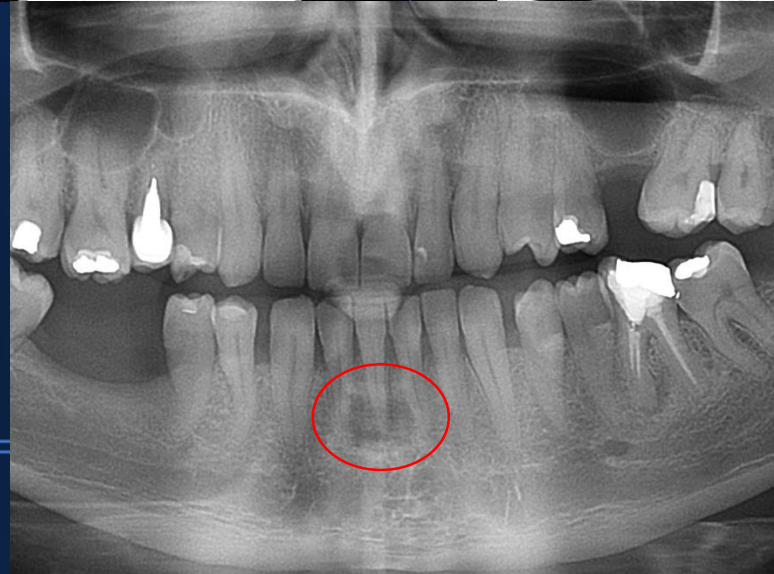
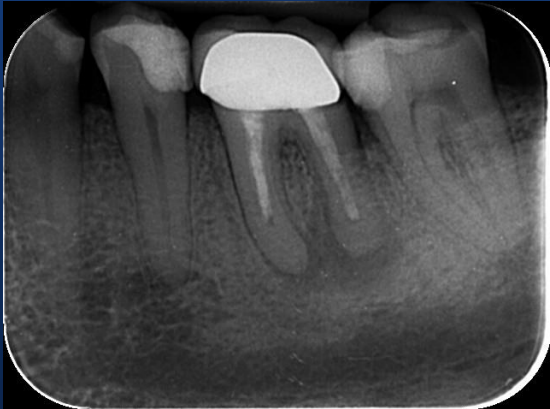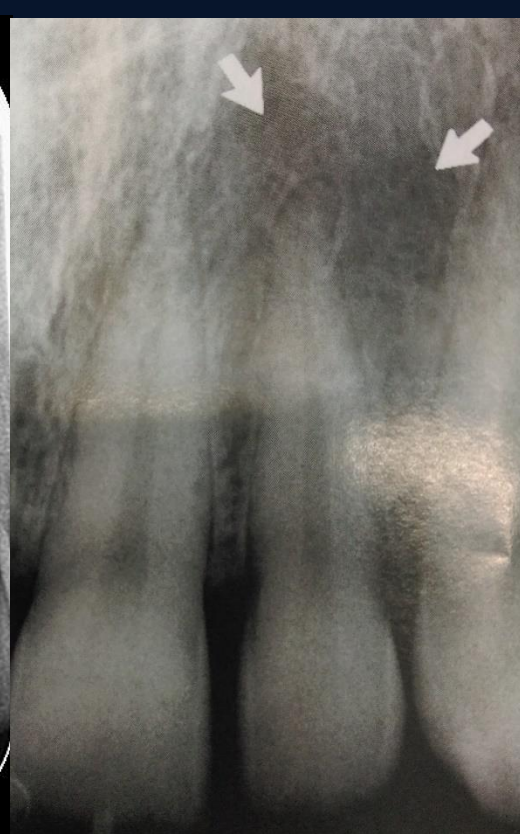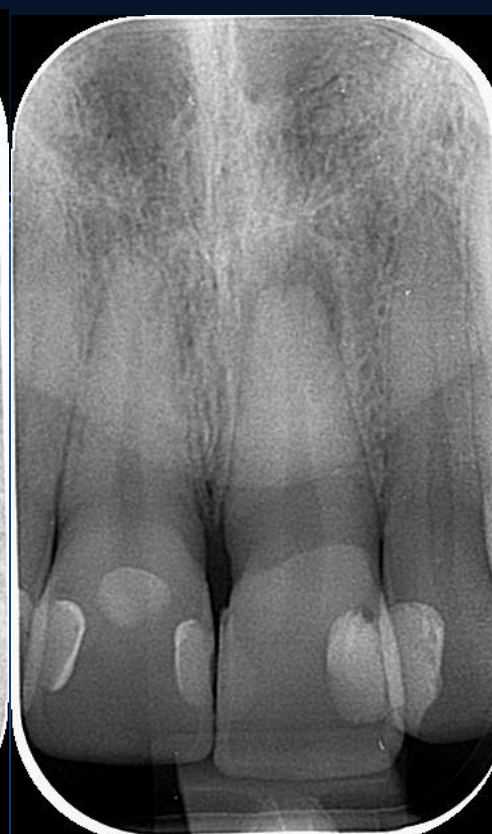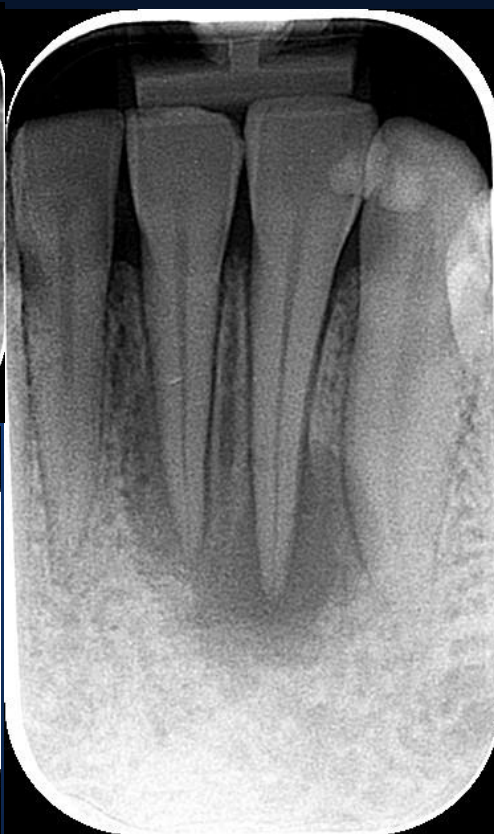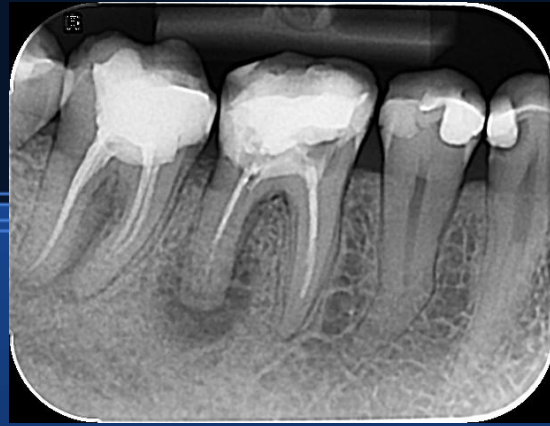Kalcificirajuća odontogena cista (Gorlinova cista)

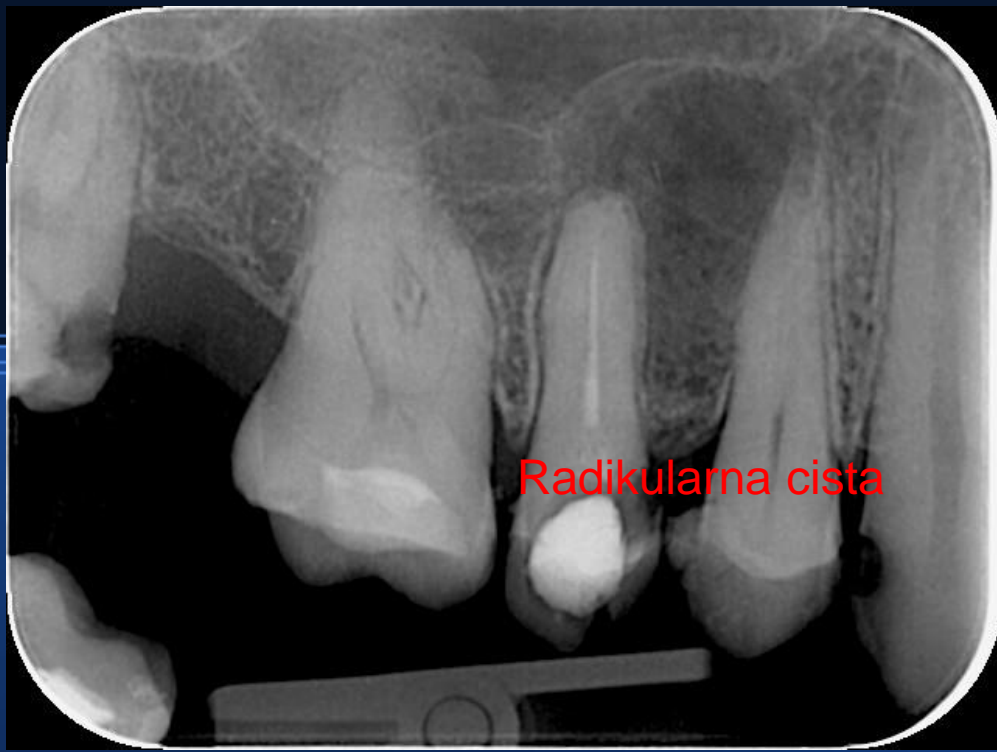


Periapikalno prosvjetljenje

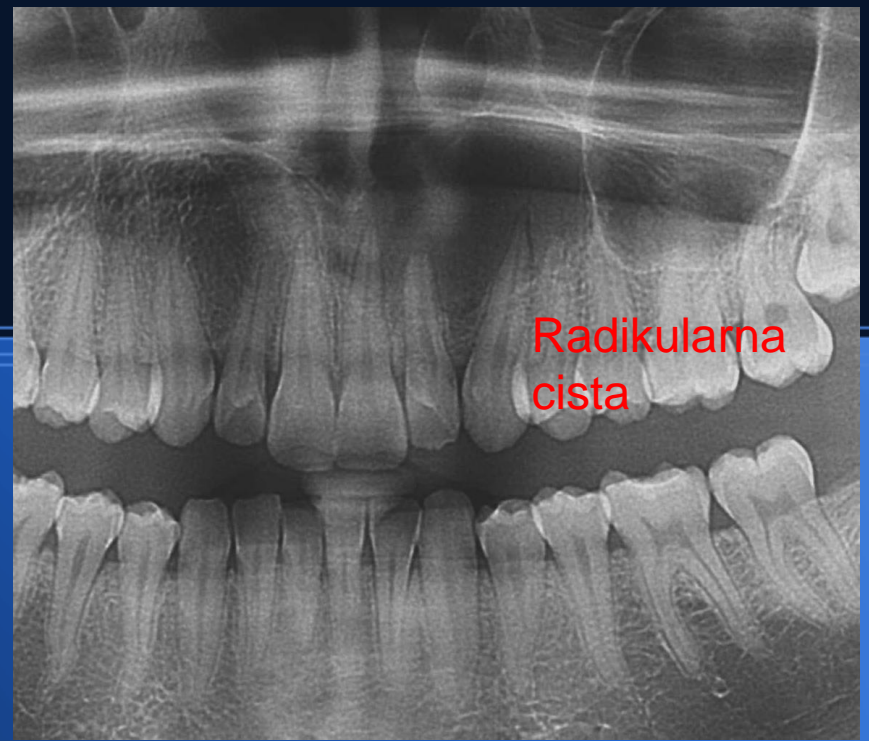
- Ostitički proces (granulom)
- Radikularna cista
- Cementno-koštana displazija
- Ožiljak...po operativnom zahvatu (fibrozno tkivo)
- Leukemija, limfom

Ostitički periapikalni proces

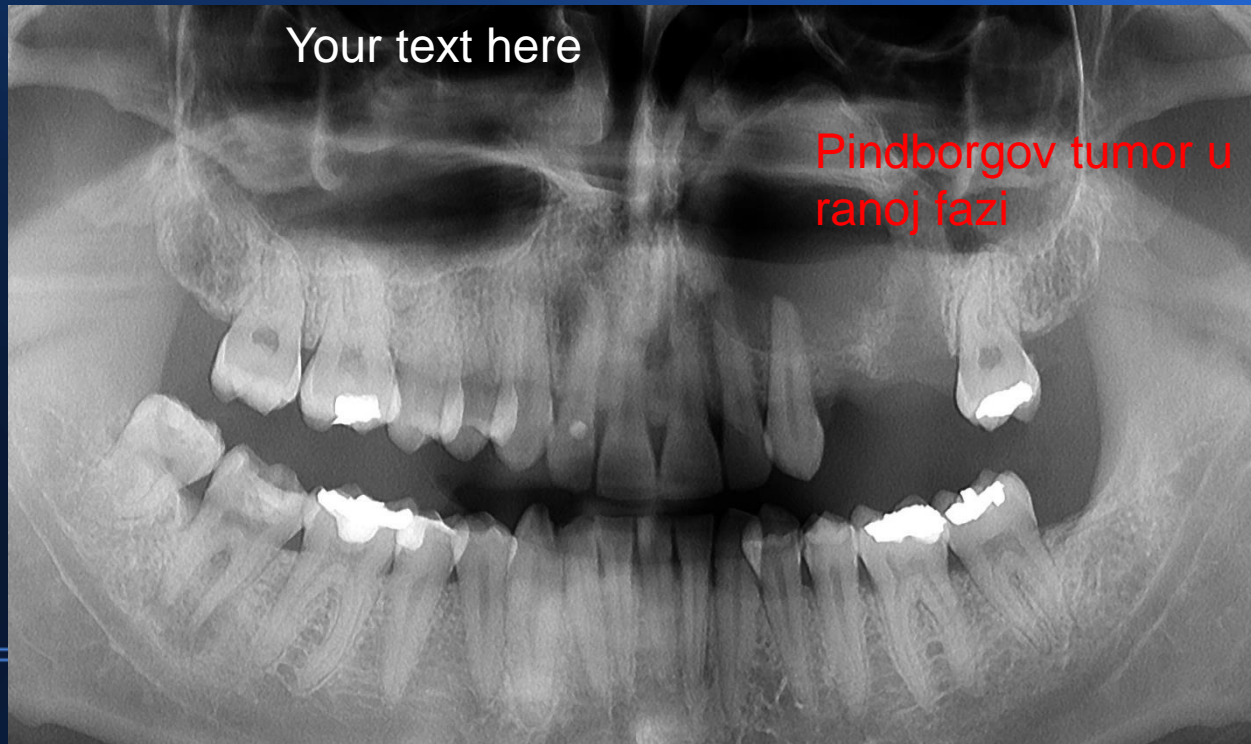




Radikularna cista



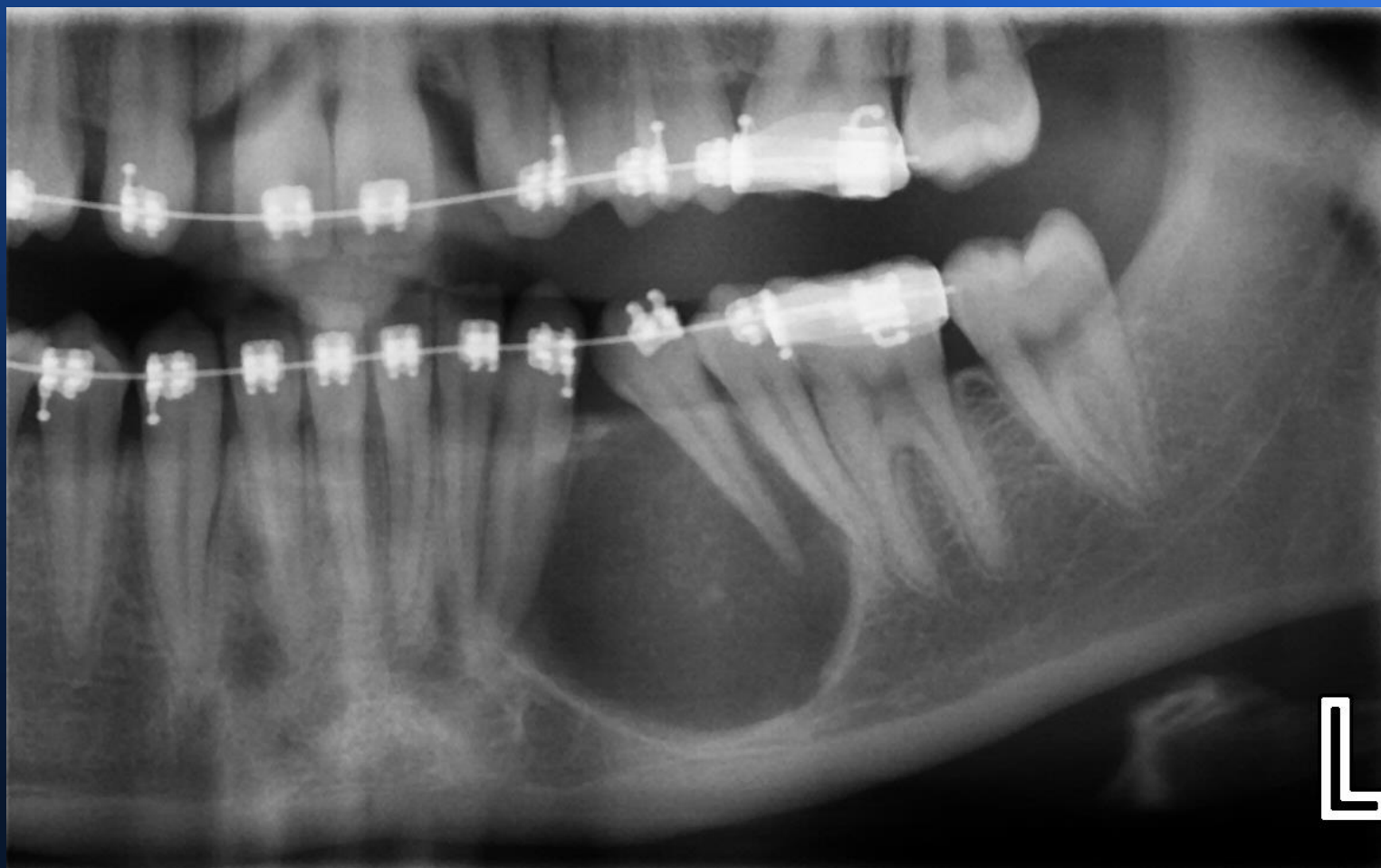Radikularna cista



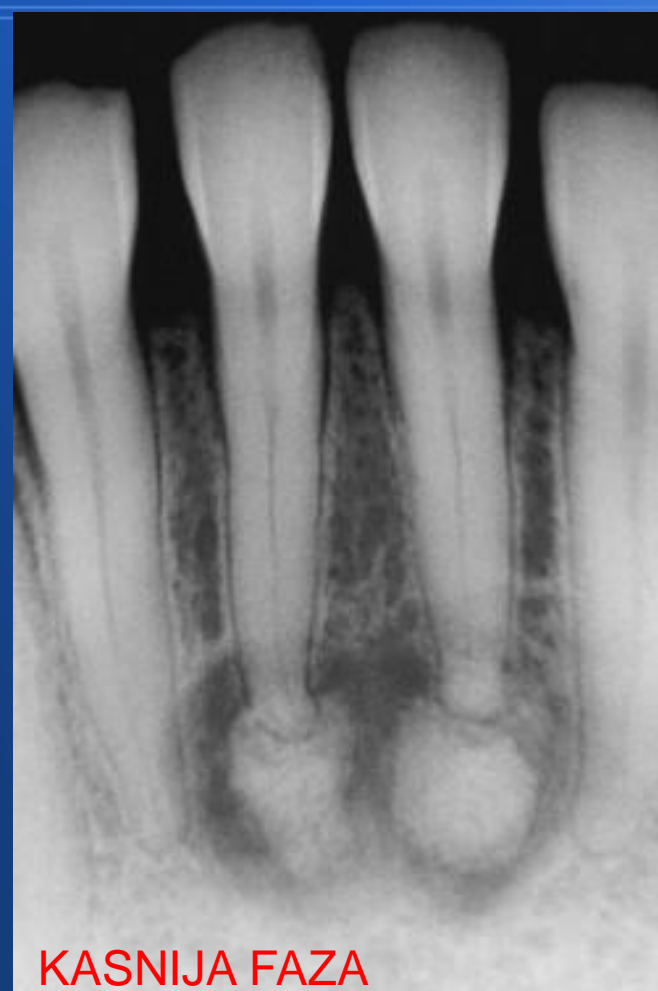
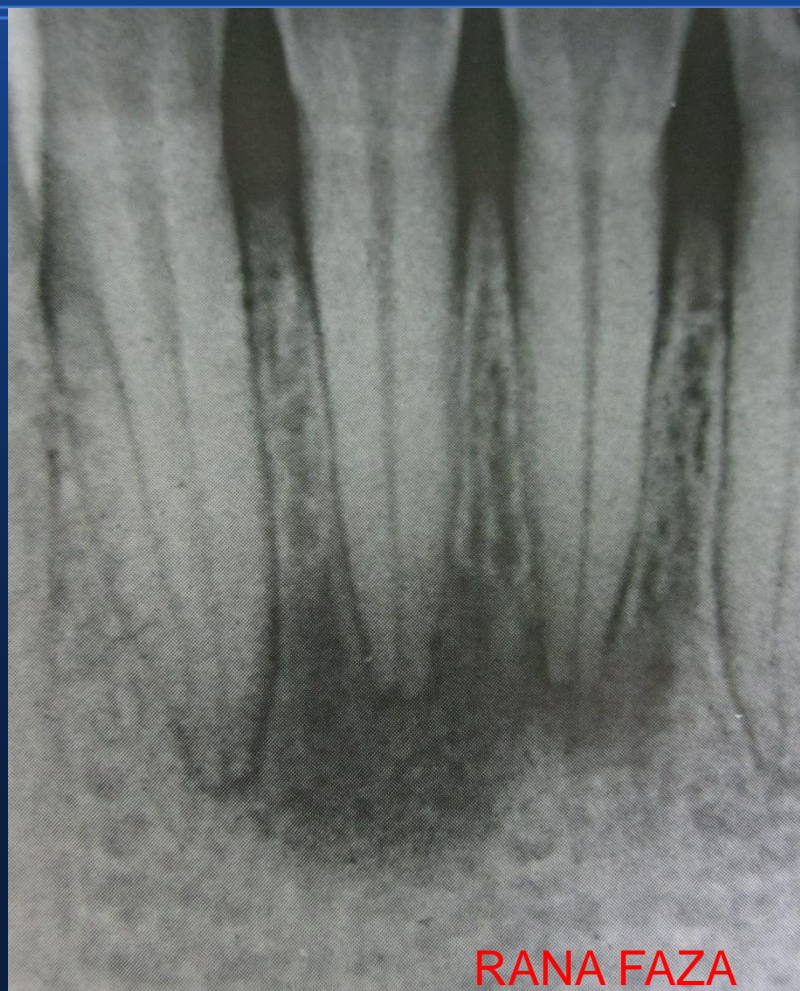
Your text here

Pindborgov tumor u ranoj fazi

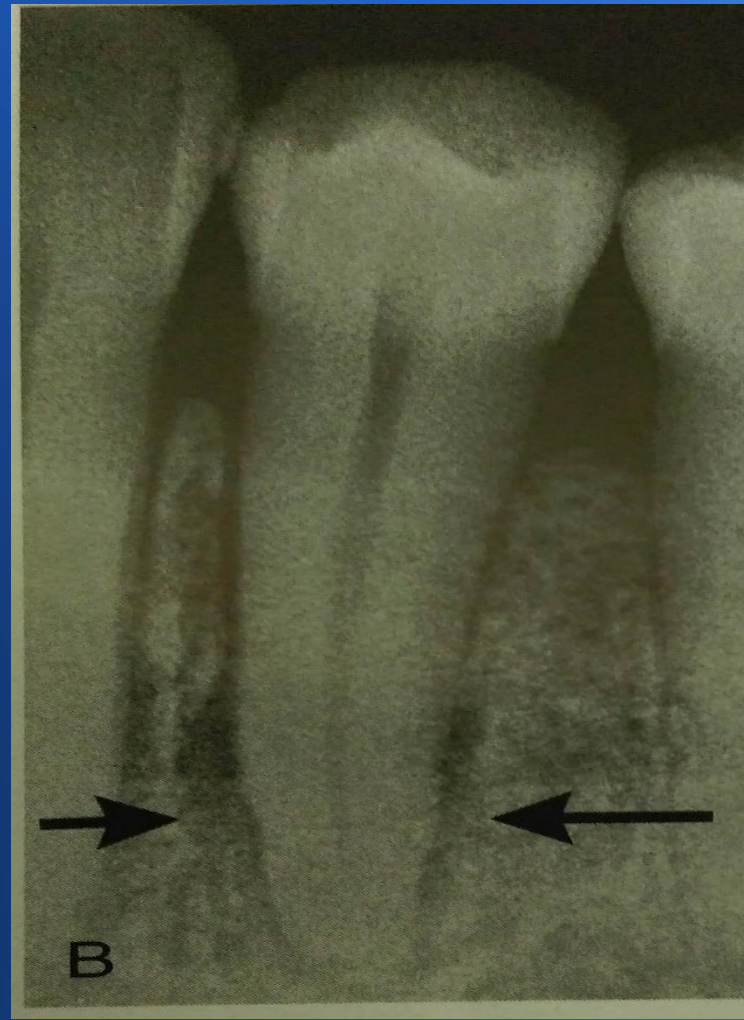
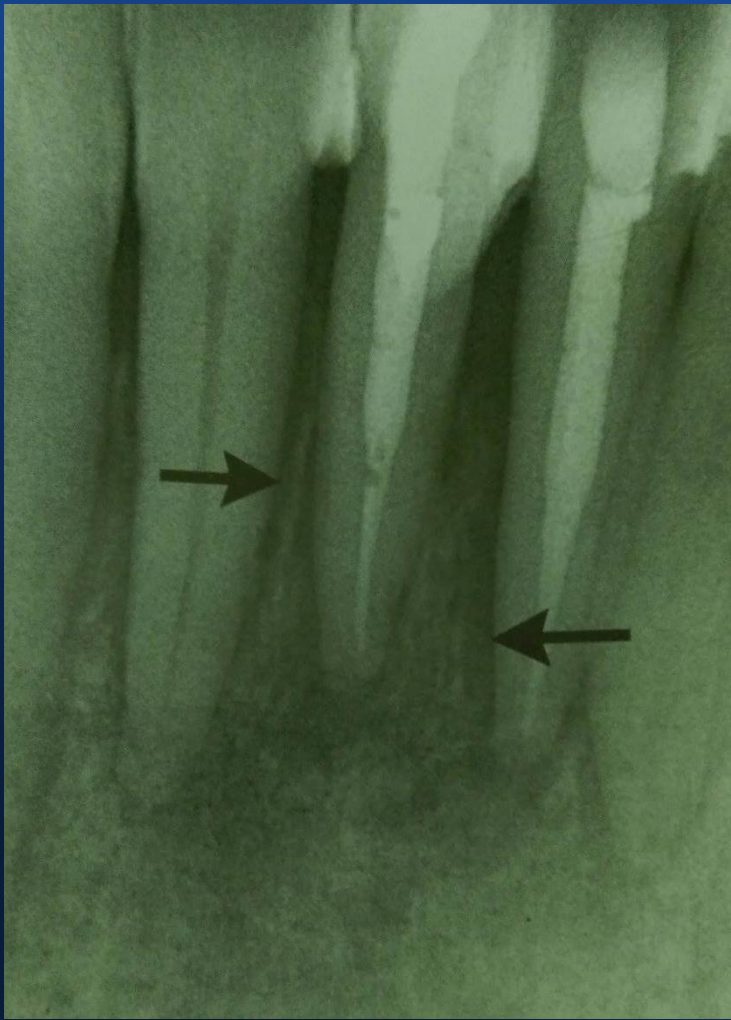
Adenomatoidni odontogeni tumor



Cementno-koštana displazija

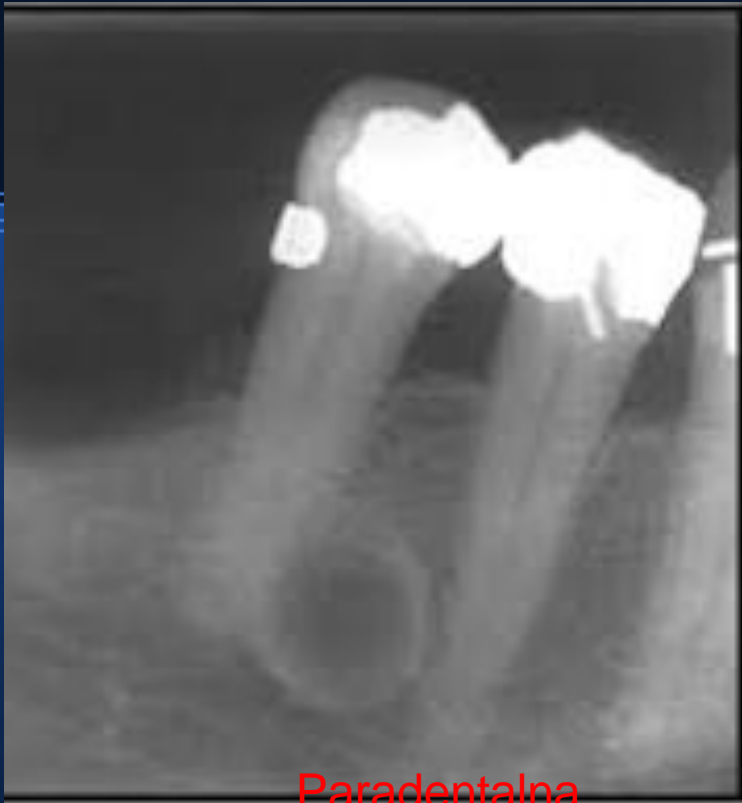

Limfom

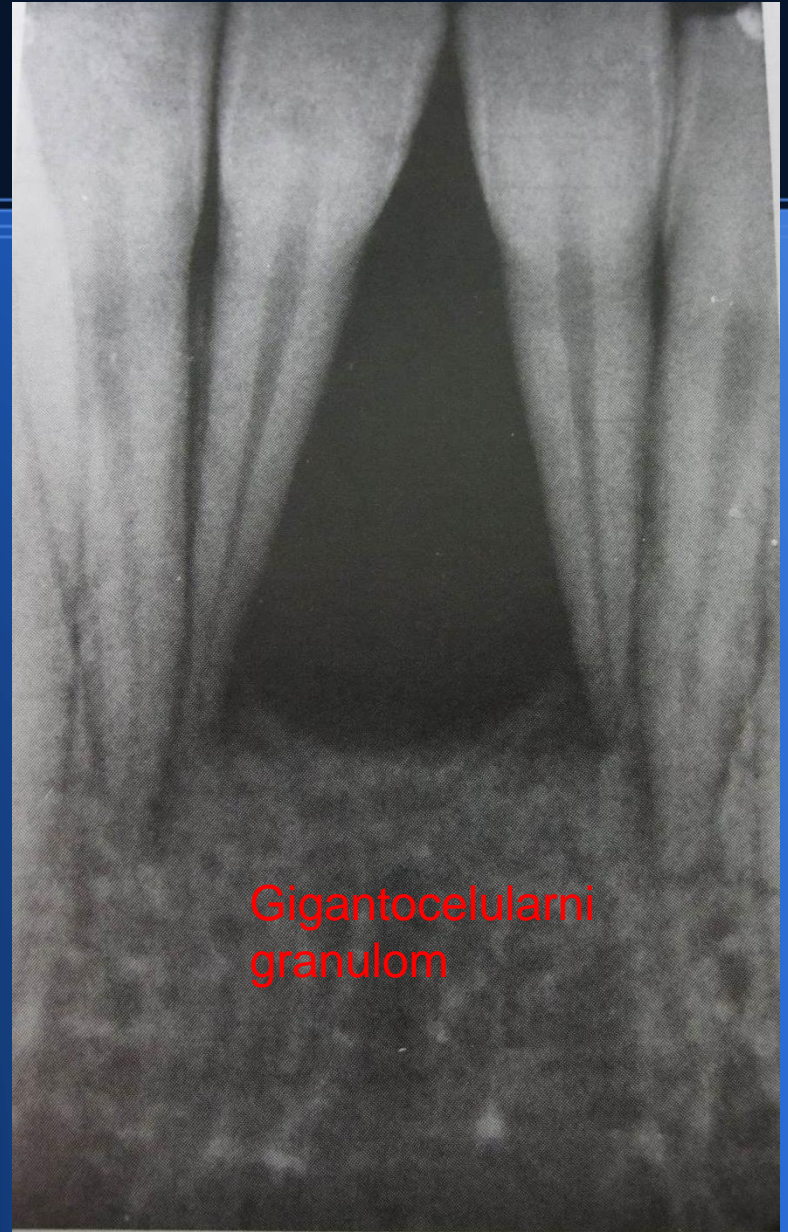
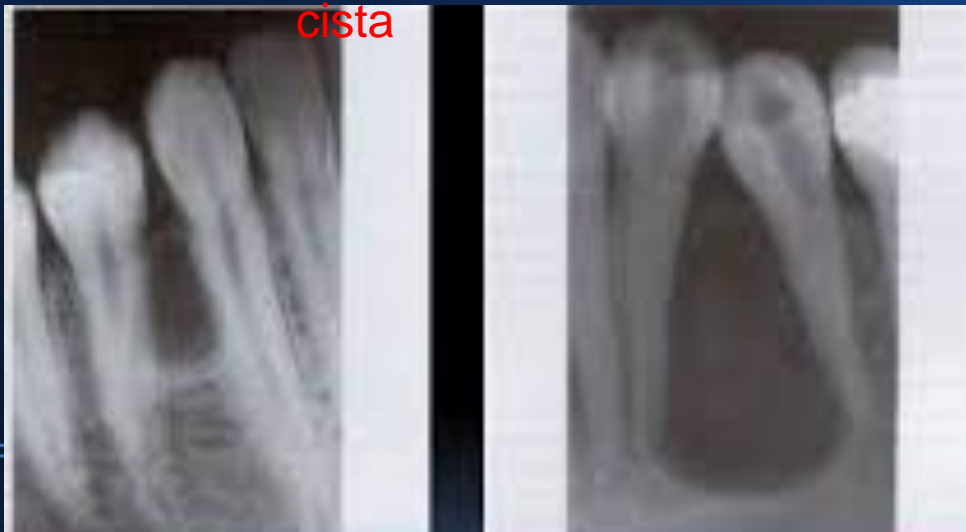


Unilokularne transparenције

- Lateralne, periodontne, rezidualne ciste
- KCOT (KERATOCISTA), centralni gigantocelularni granulom
- Stafneova cista, idiopatska koštana šupljina
- Ameloblastom unicistični
- histiocitoza

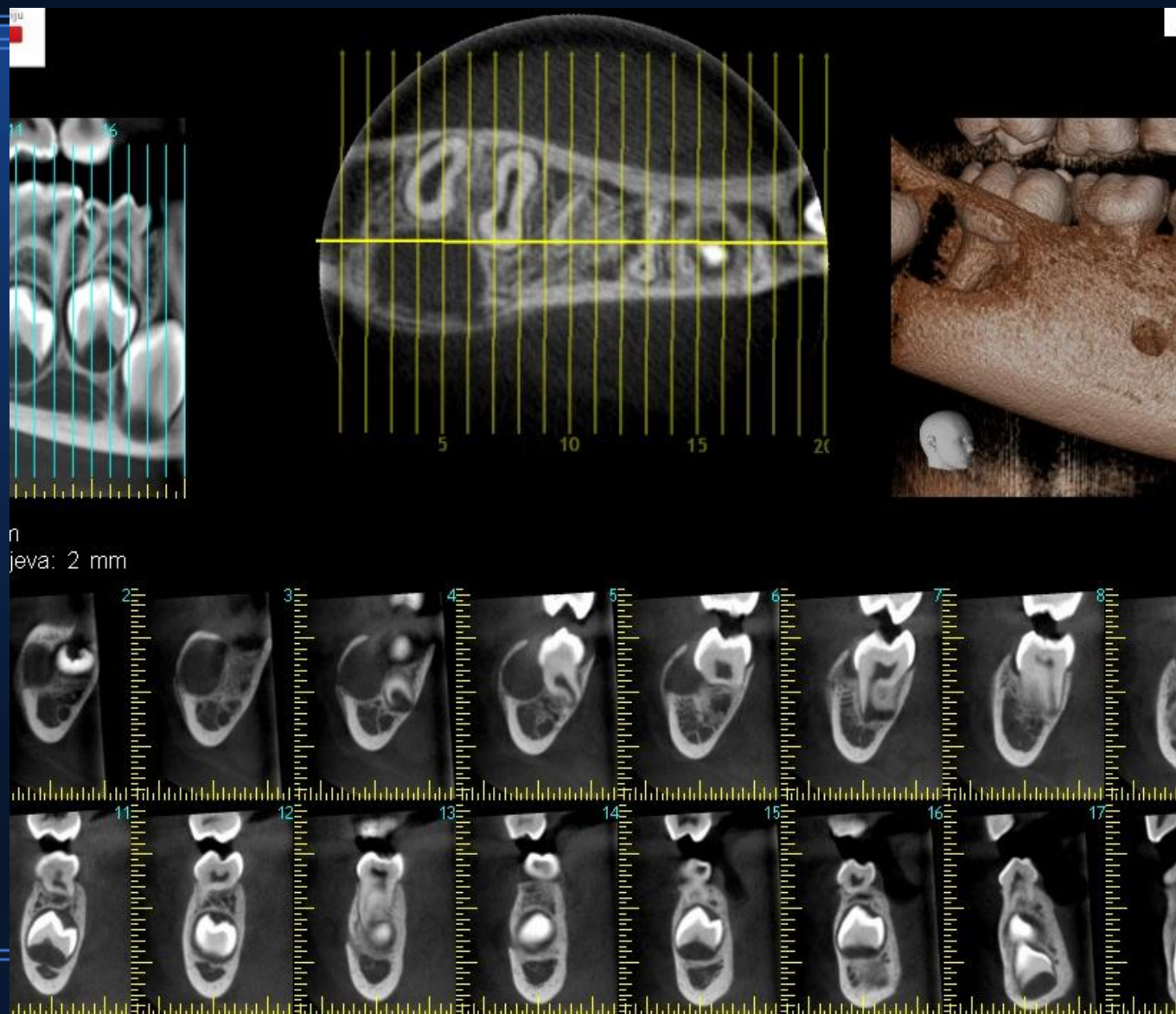


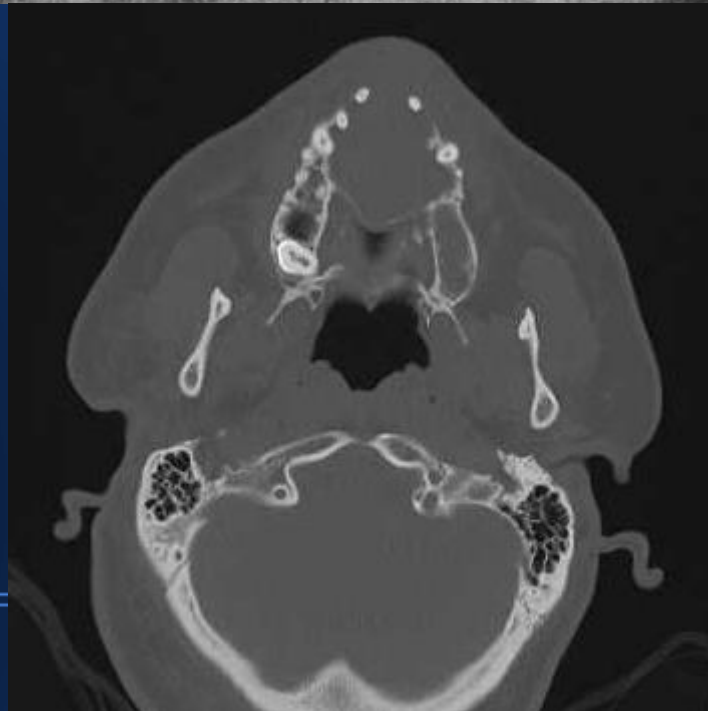
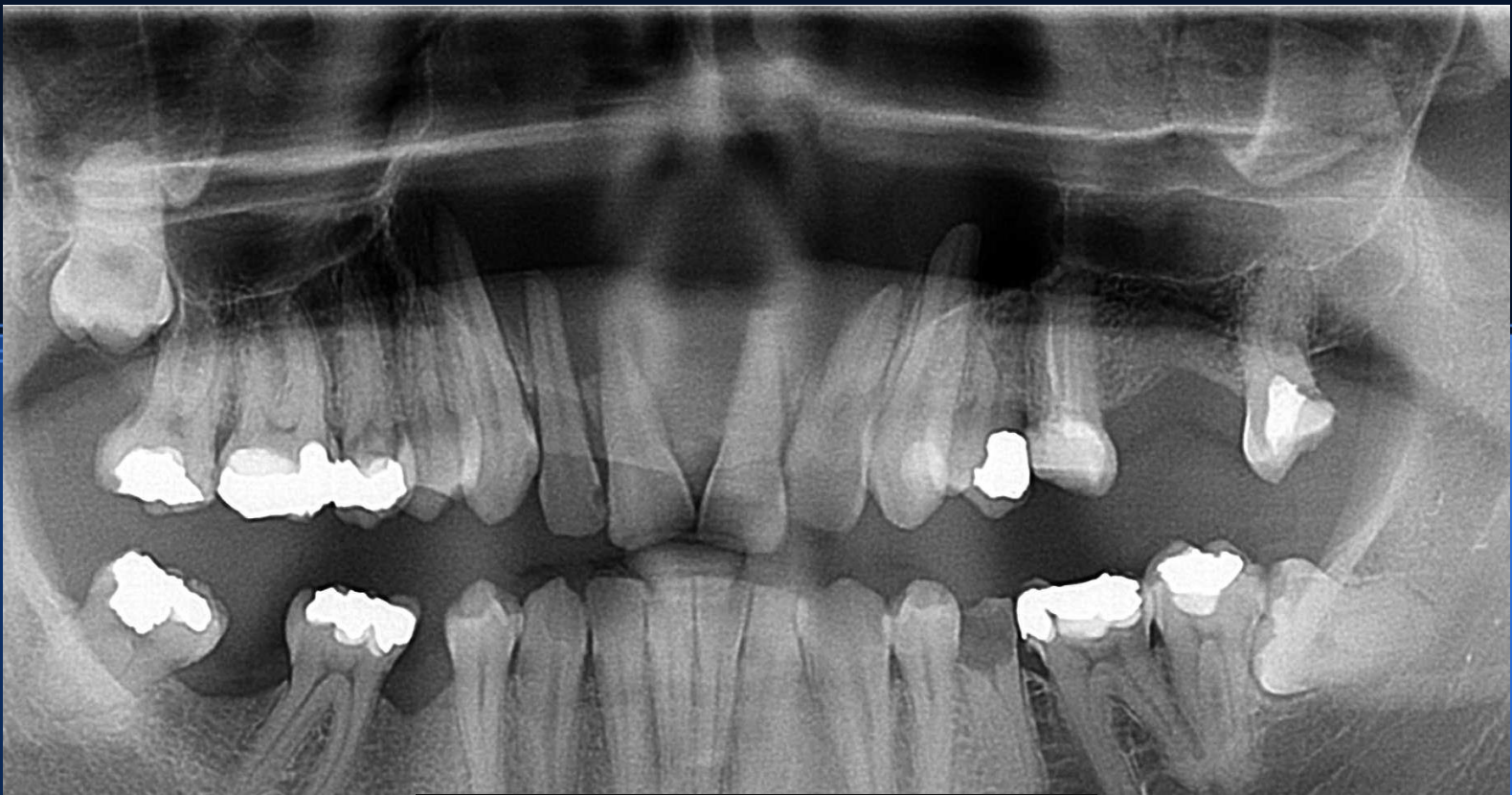
Paradentalna
cista



Gigantocelularni
granulom

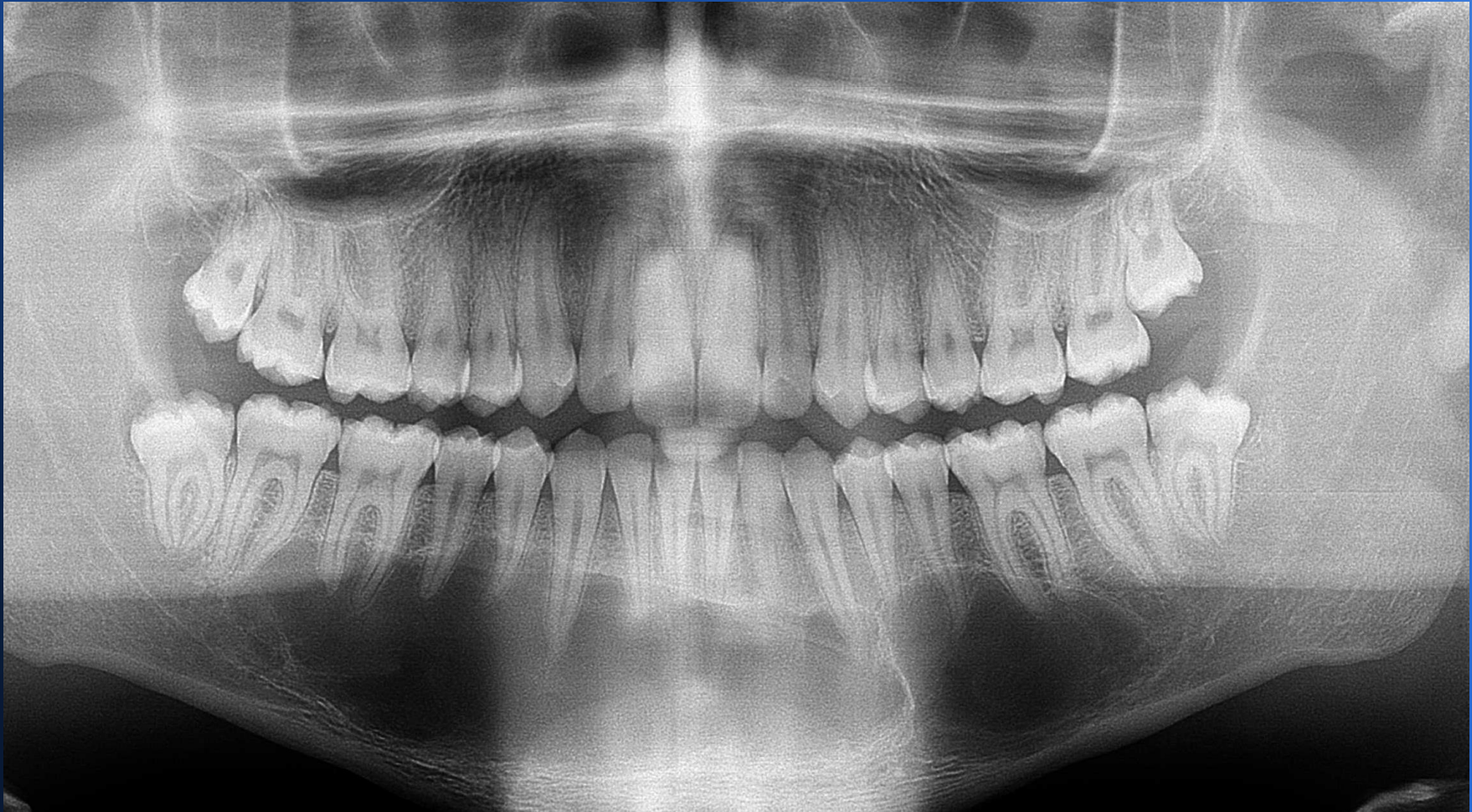Bukalna bifurkacijska cista

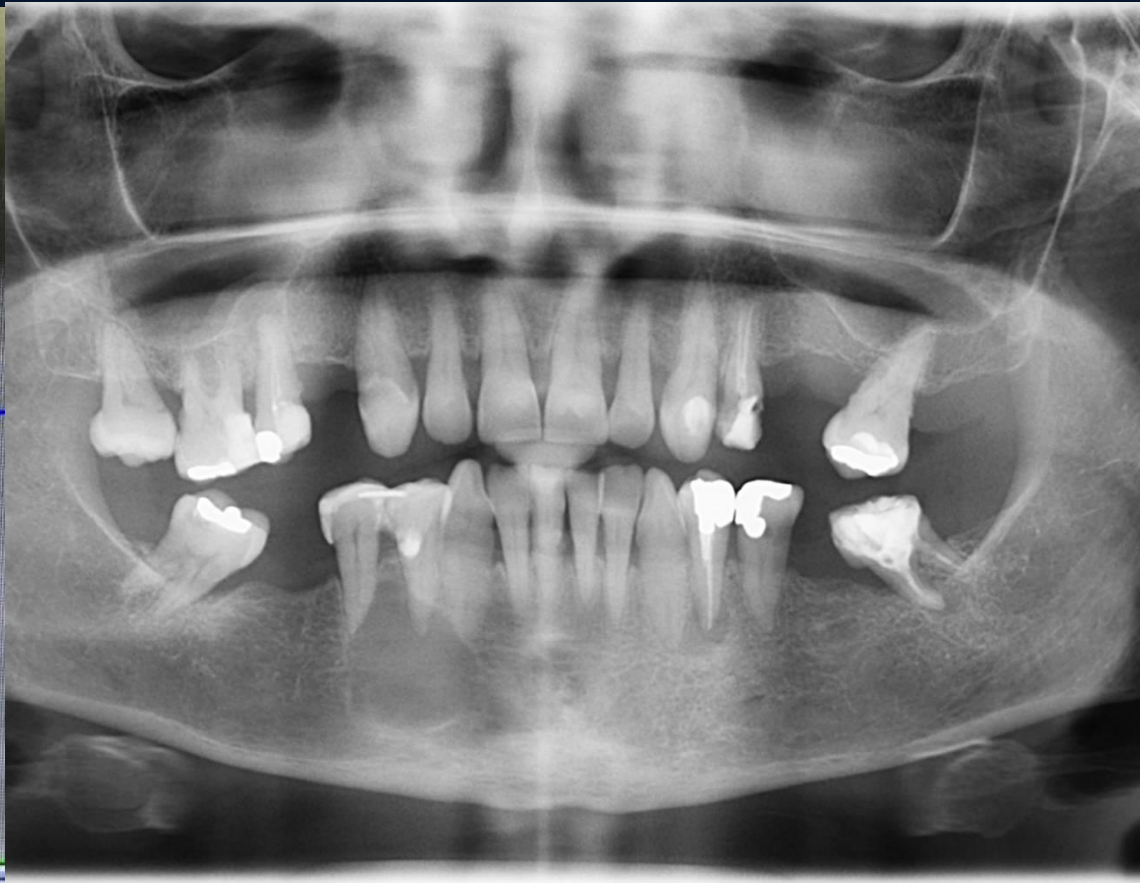
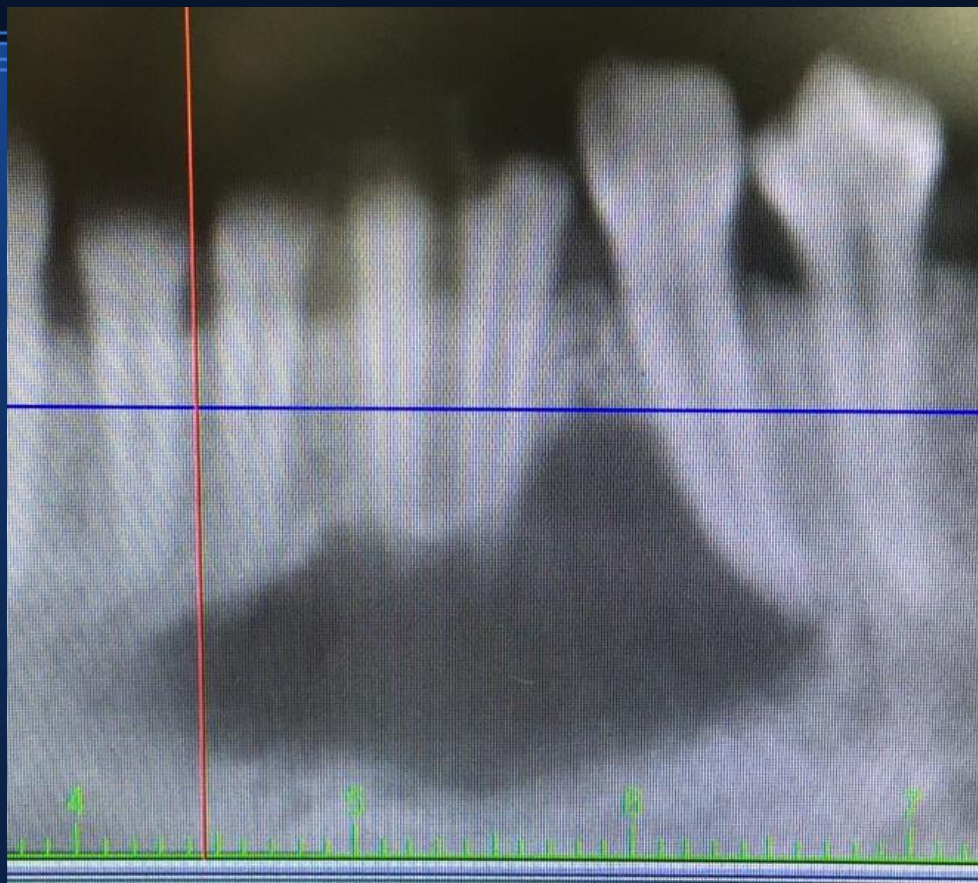


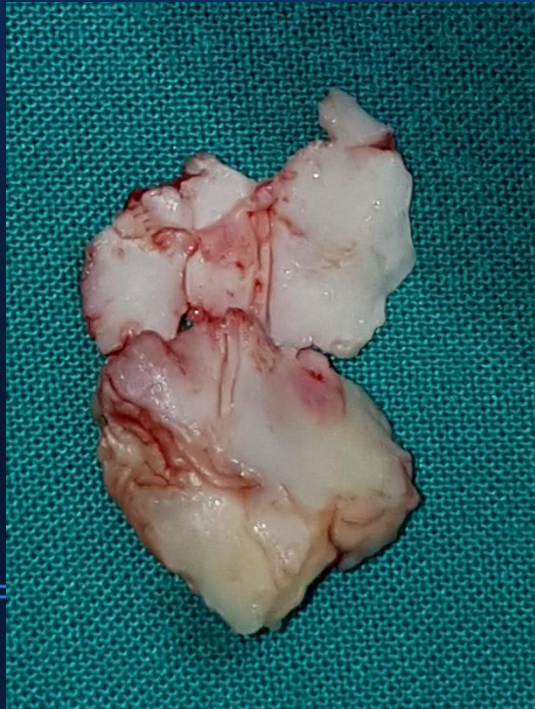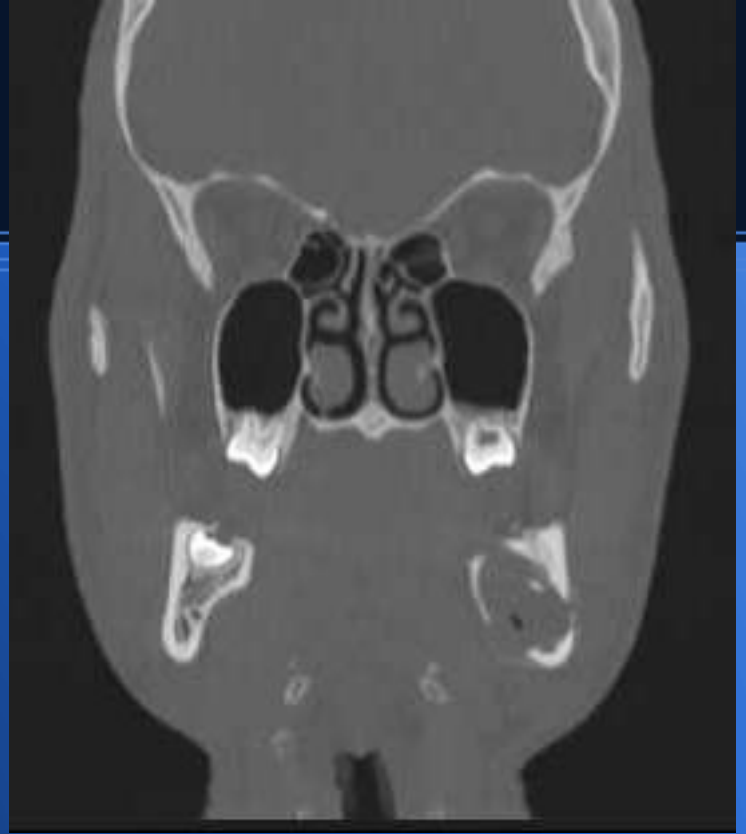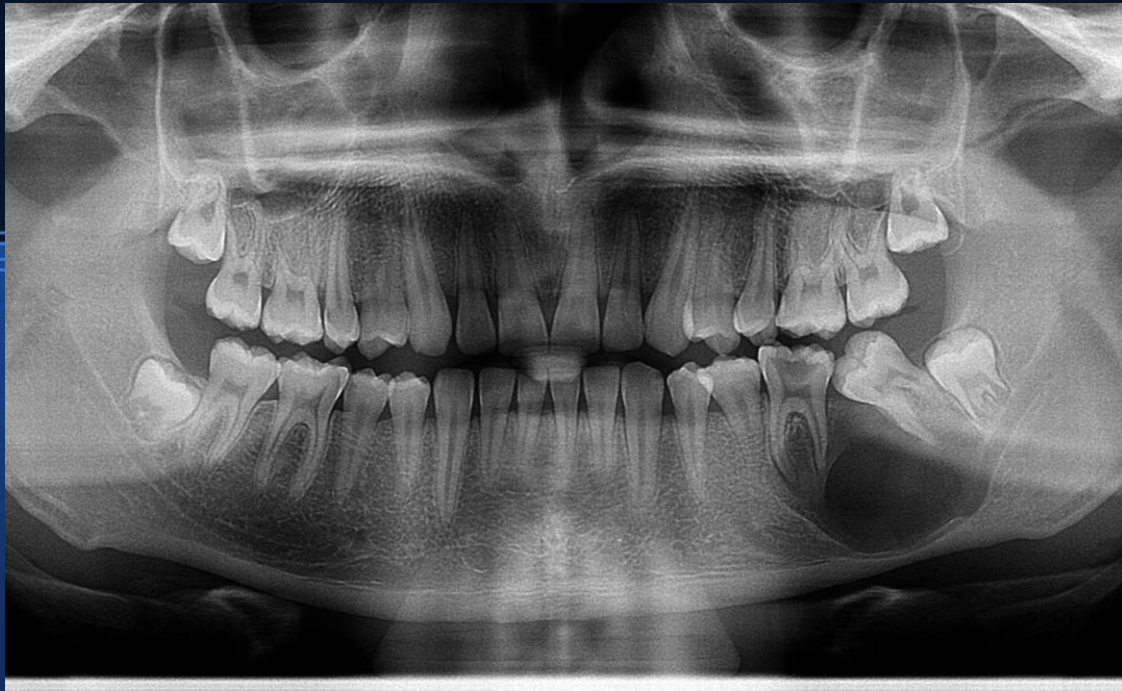Cista nasopalatinalnog
duktusa

Idiopatska koštana šupljina- svi zubi na ovom ortopanu su vitalni!!!

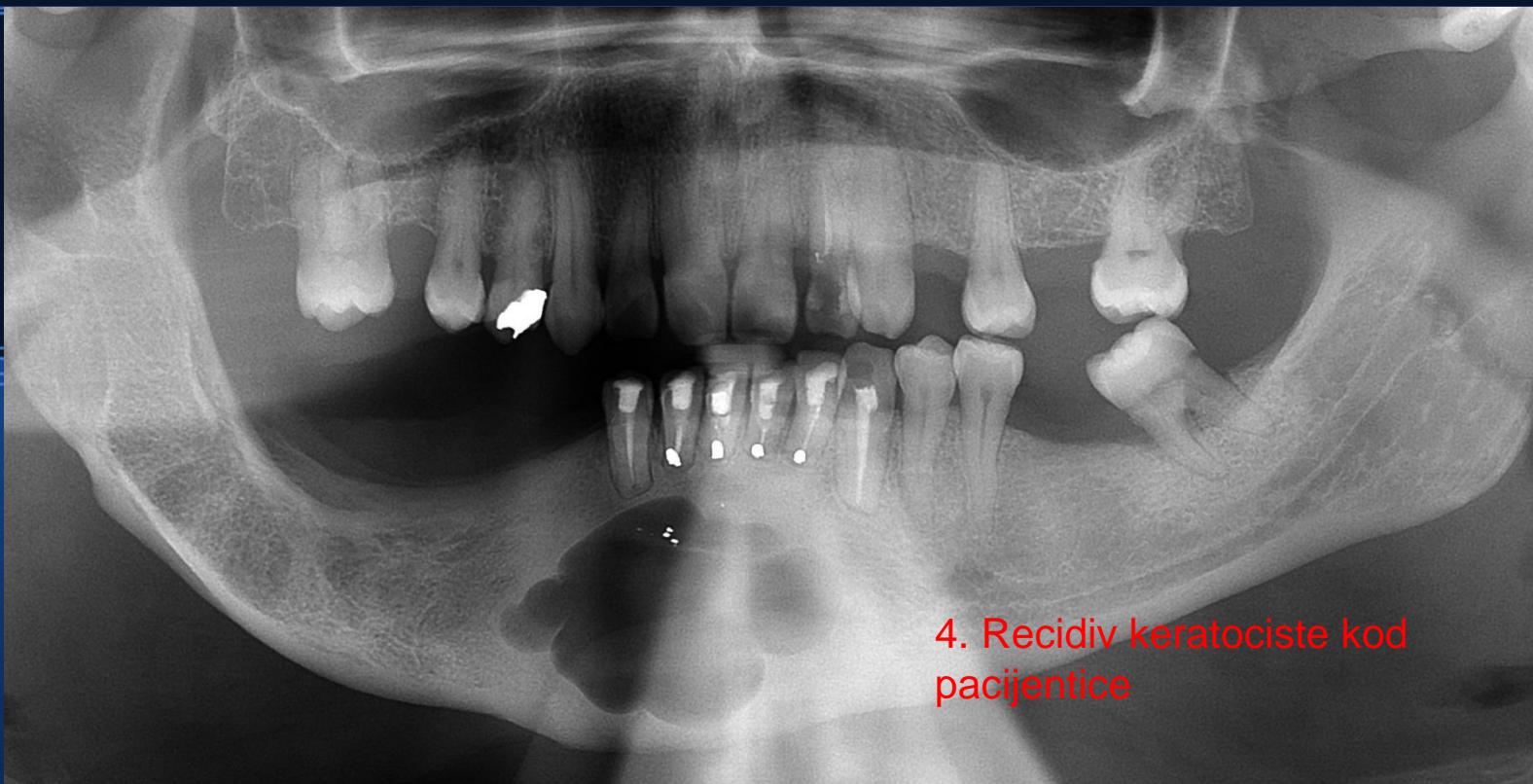




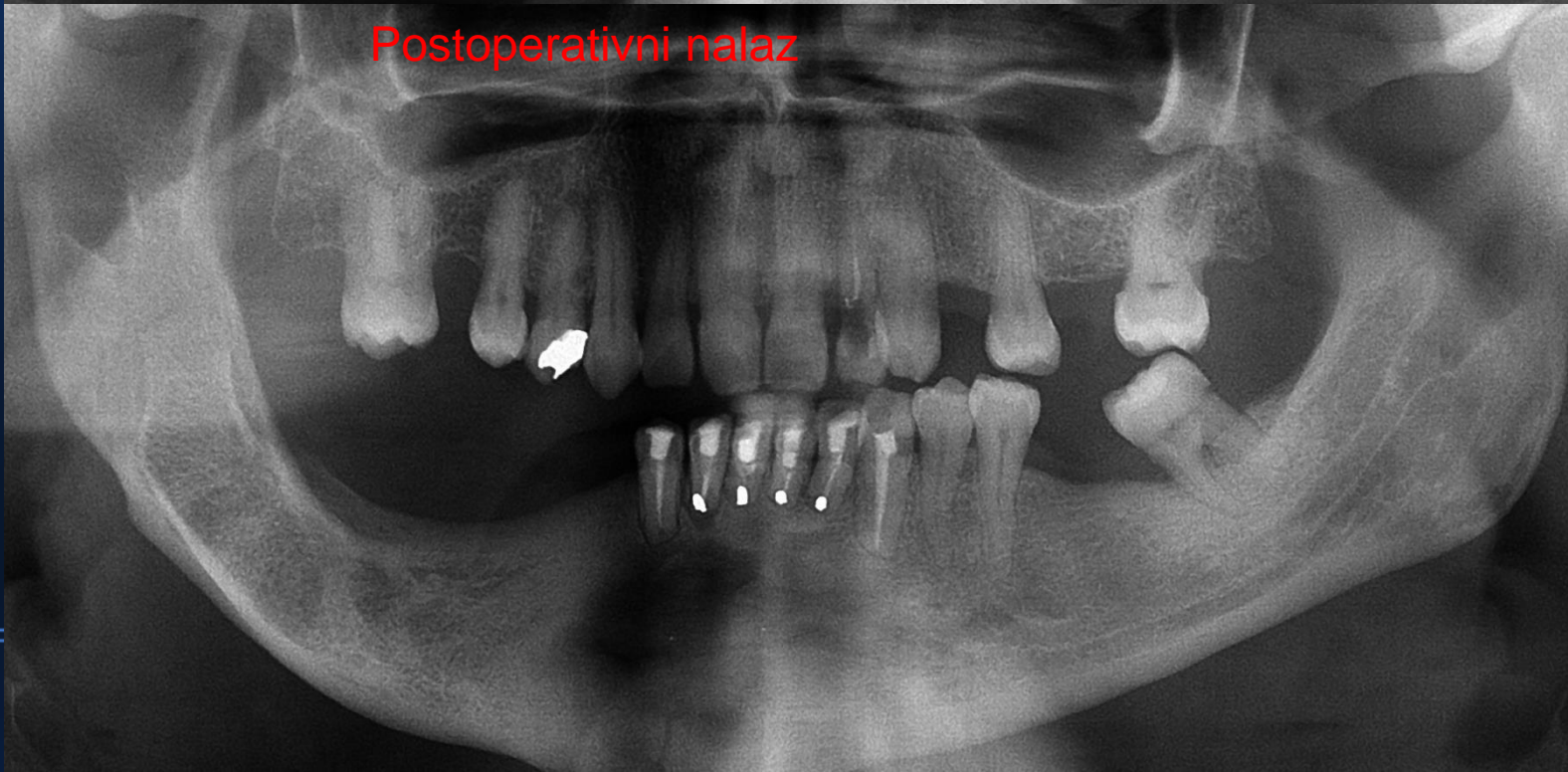
Keratociste-keratocistični odontogeni tumor



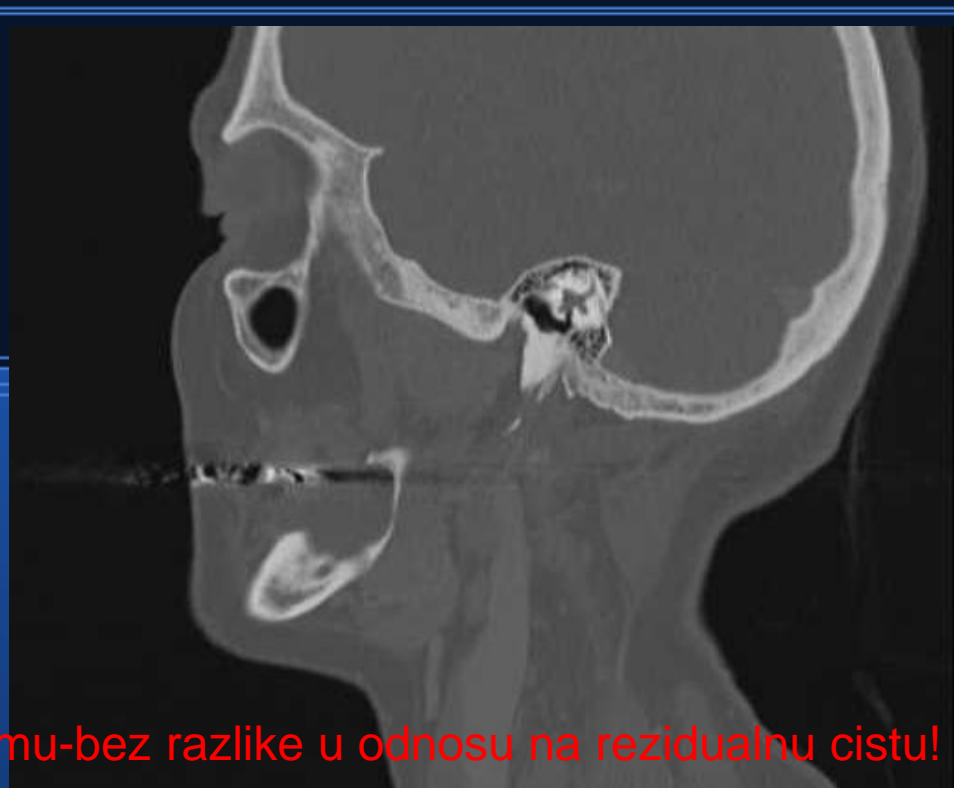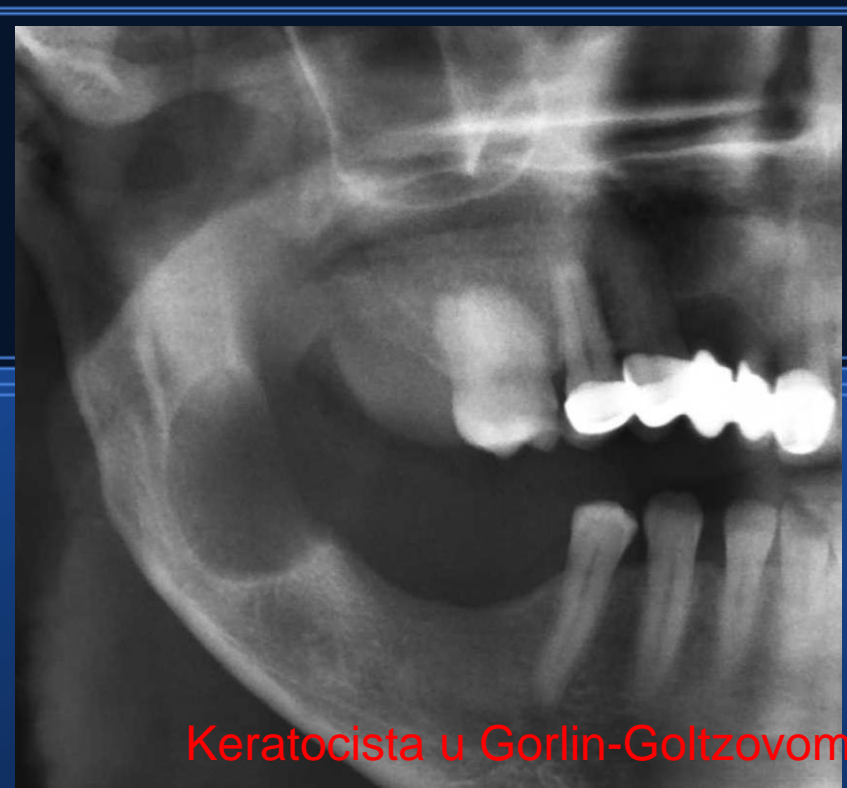Keratocista



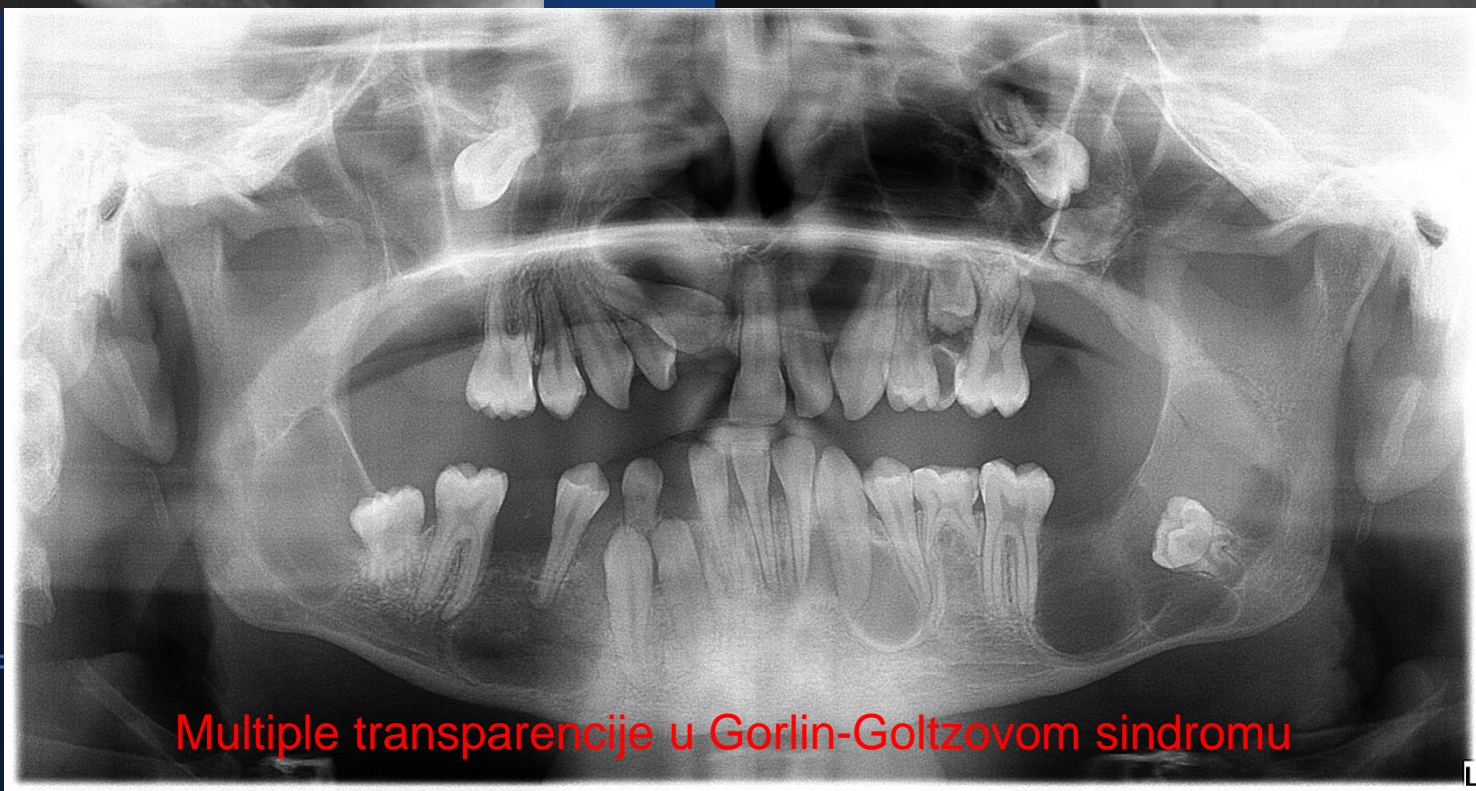
4. Recidiv keratociste kod pacijentice



Postoperativni nalaz

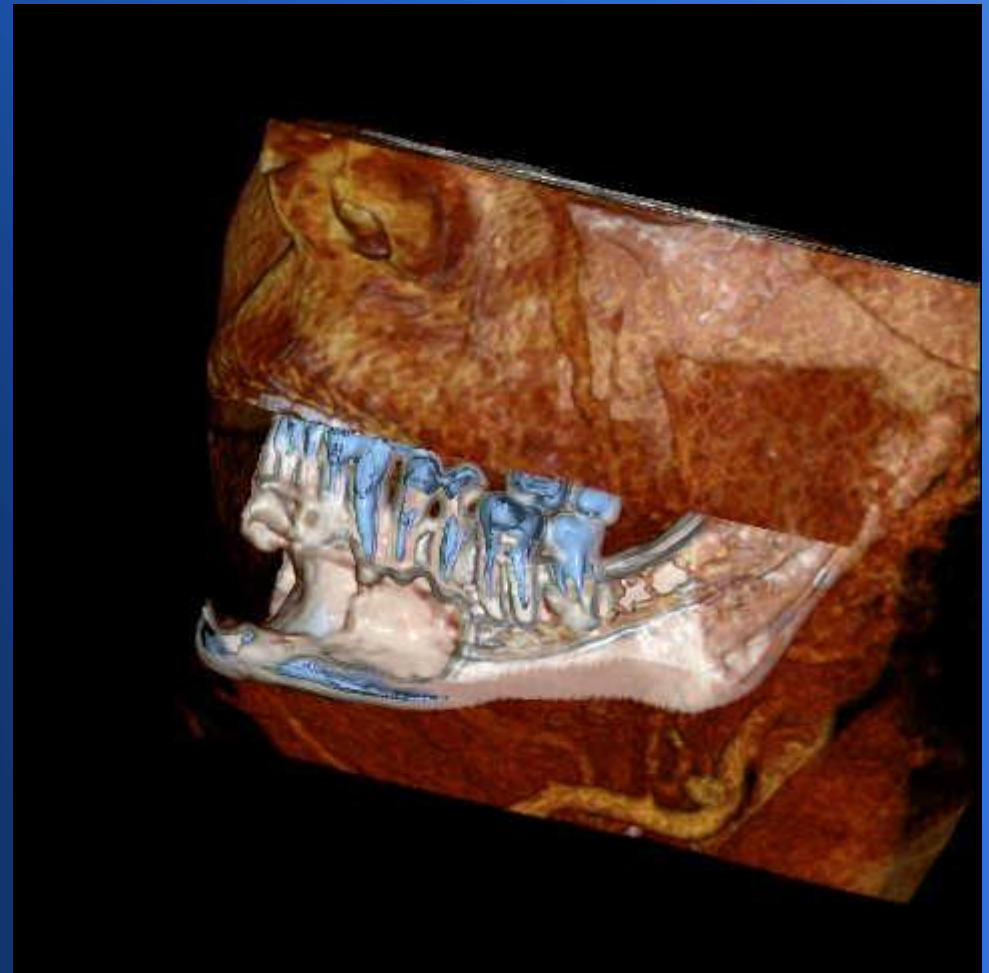
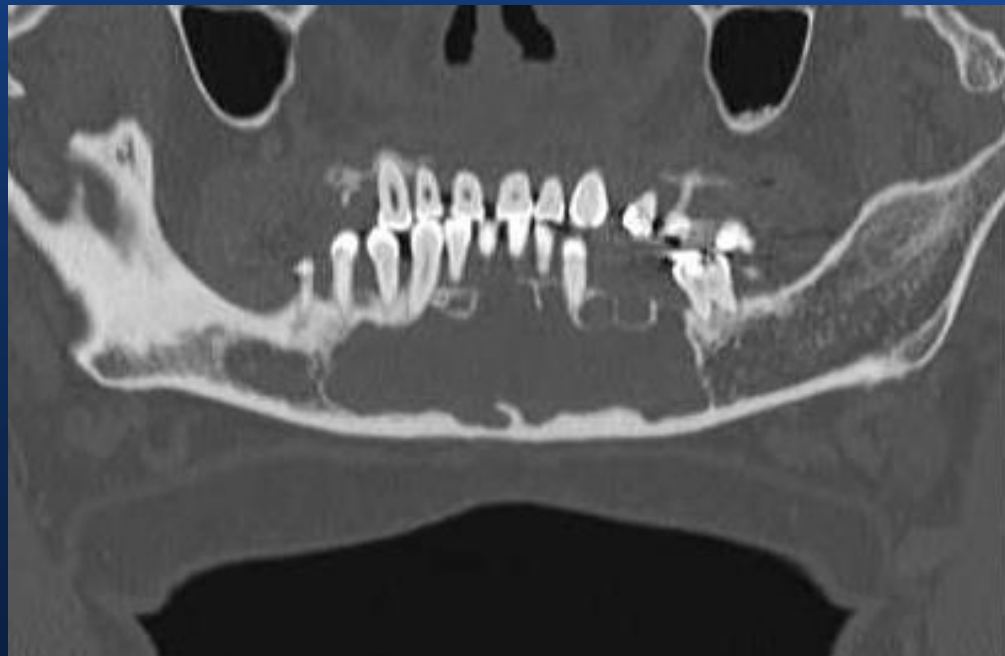

Keratocista u Gorlin-Goltzovom sindromu-bez razlike u odnosu na rezidualnu cistu!

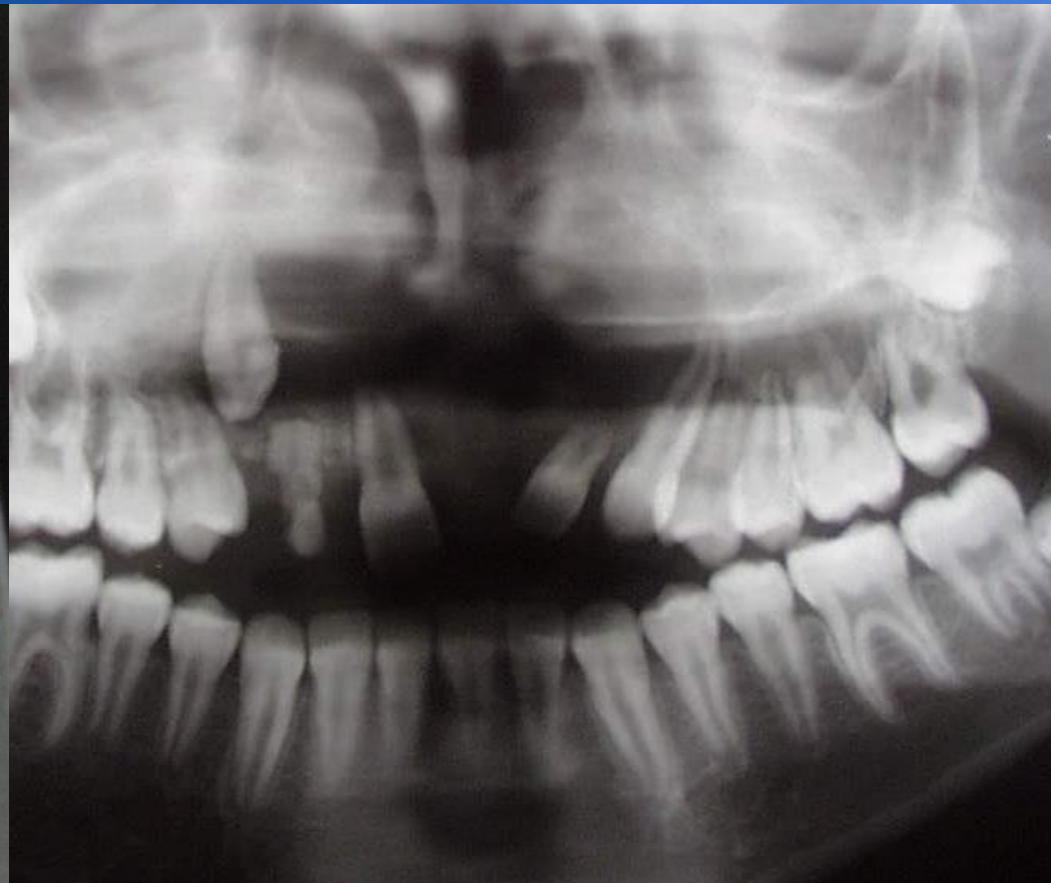
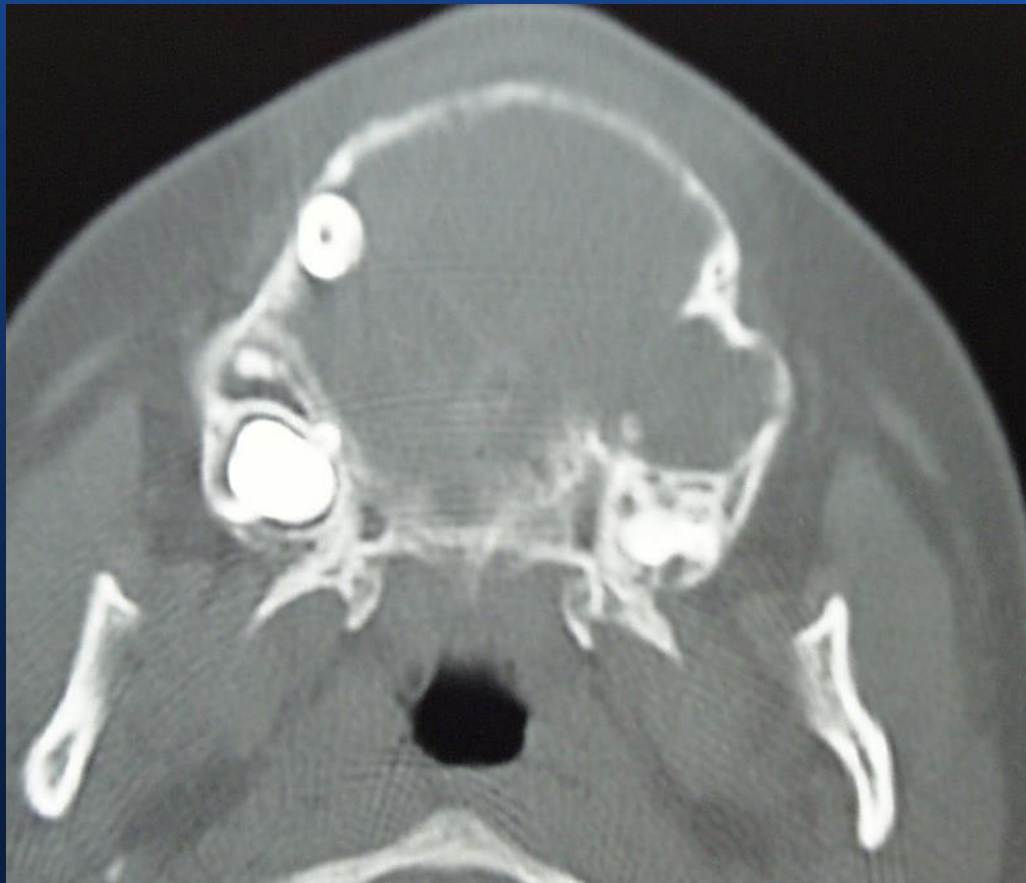
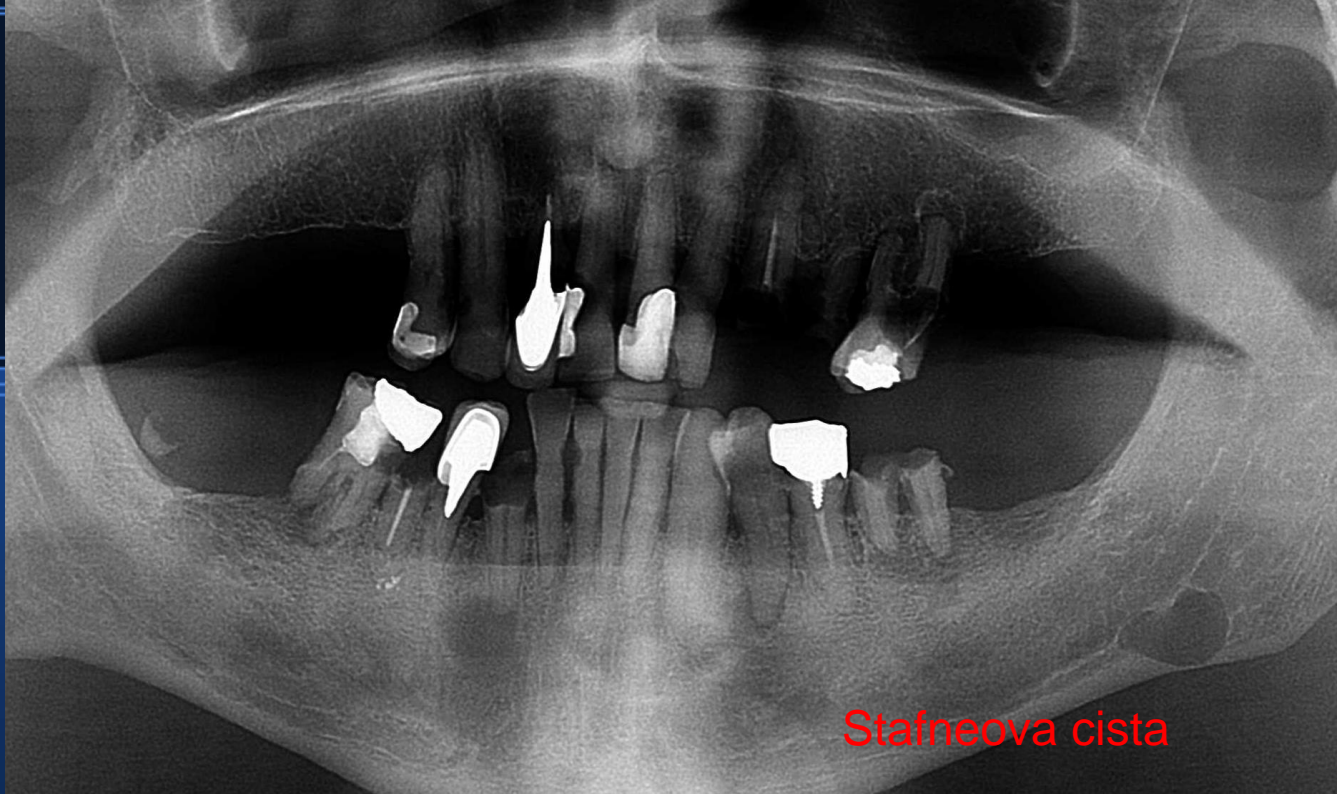
Multiple transparencije u Gorlin-Goltzovom sindromu

Botrioidna cista-vrsta periodontne ciste

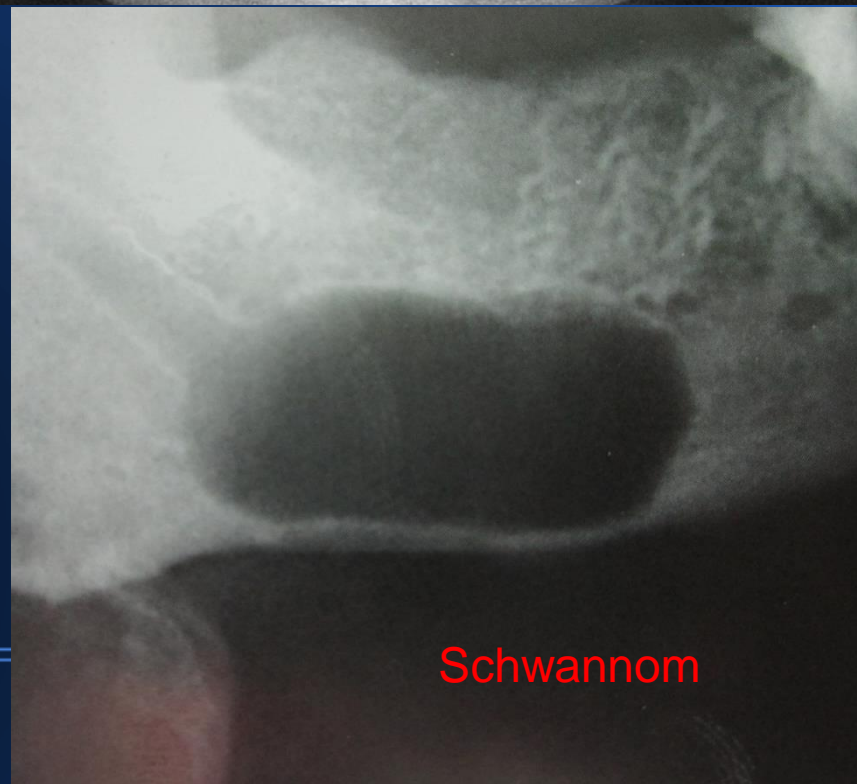

Centralni gigantocelularni granulom



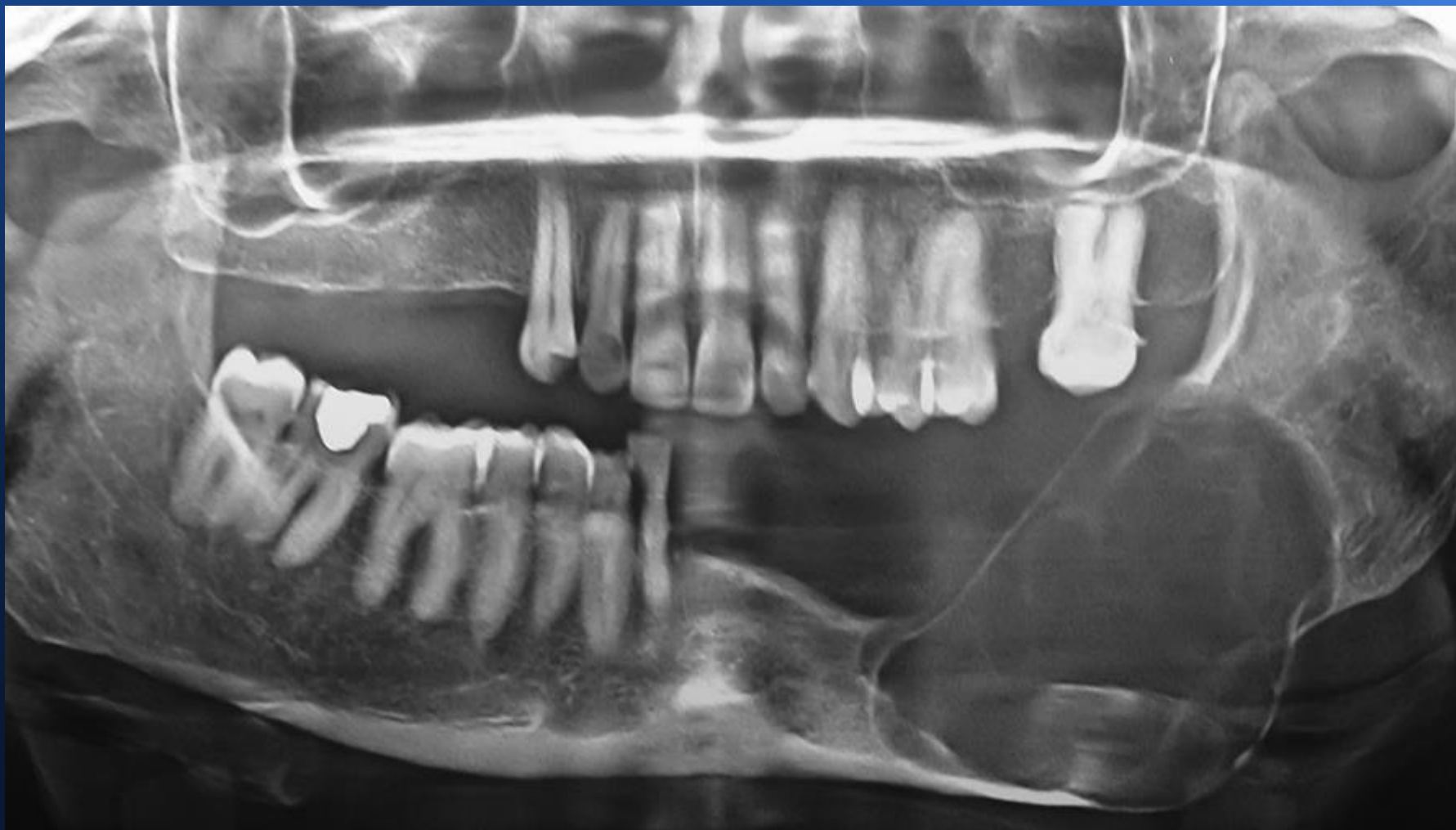

Stafneova cista



Schwannom

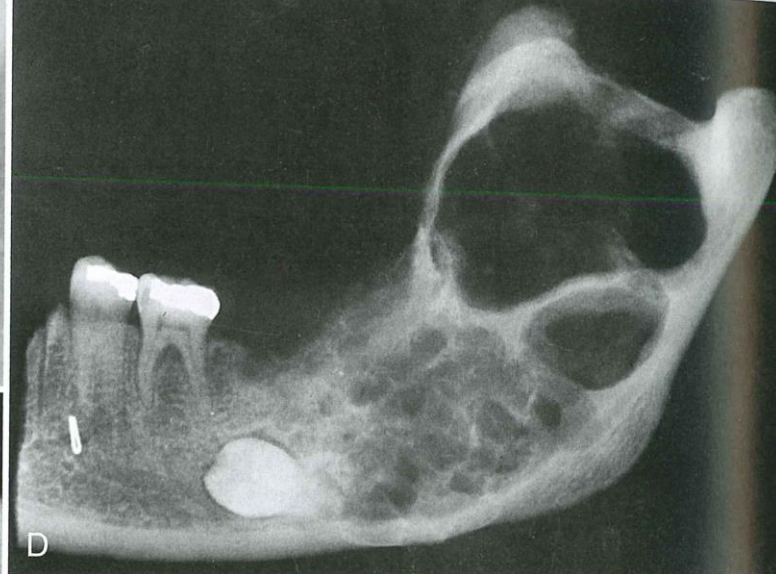
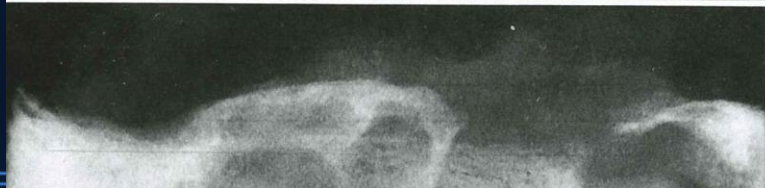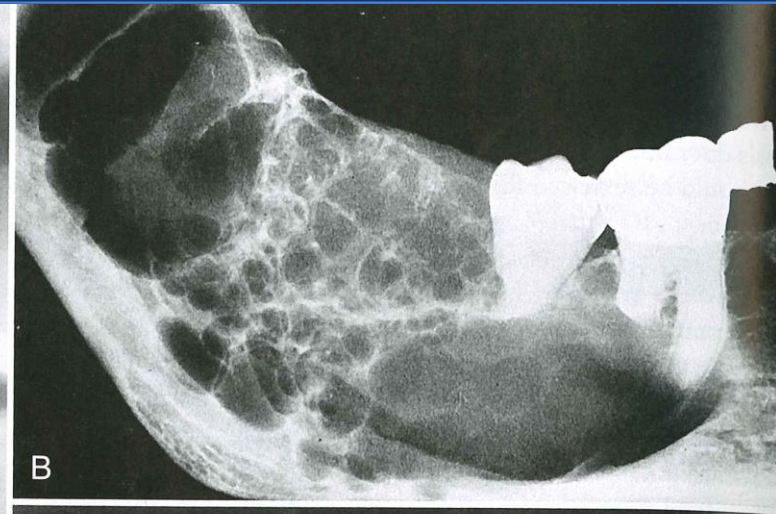
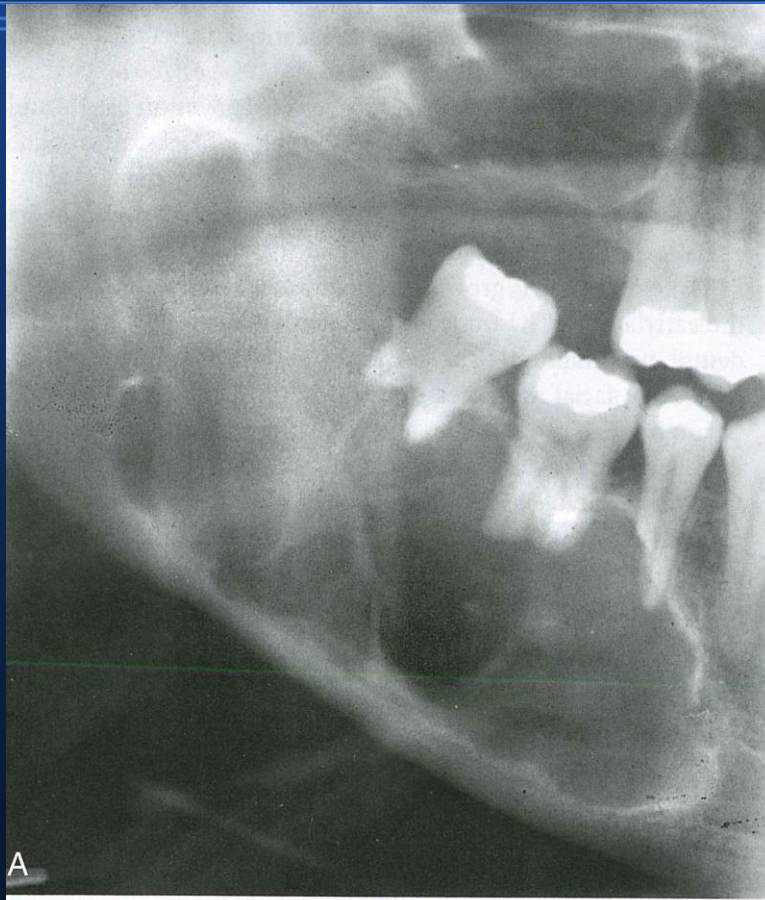
Unicistični ameloblastom

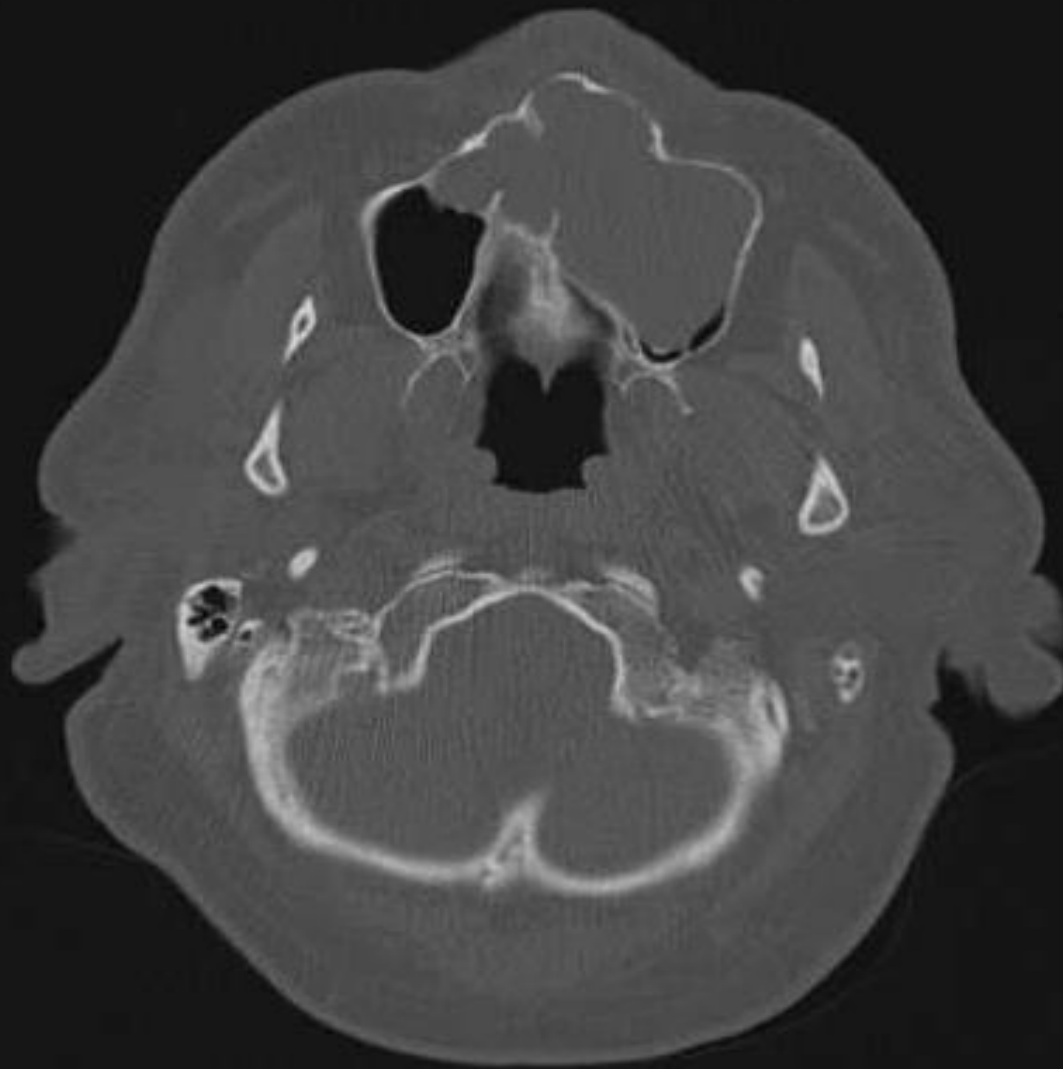

Multilokularne transparencije

- KCOT, ameloblastom
- Centralni gigantocelularni granulom
- Odontogeni miksom
- Centralni hemangiom
- Aneurizmatska koštana cista
- Kerubizam
- Koštani mukoepidermoidni karcinom
- Glandularna odontogena cista

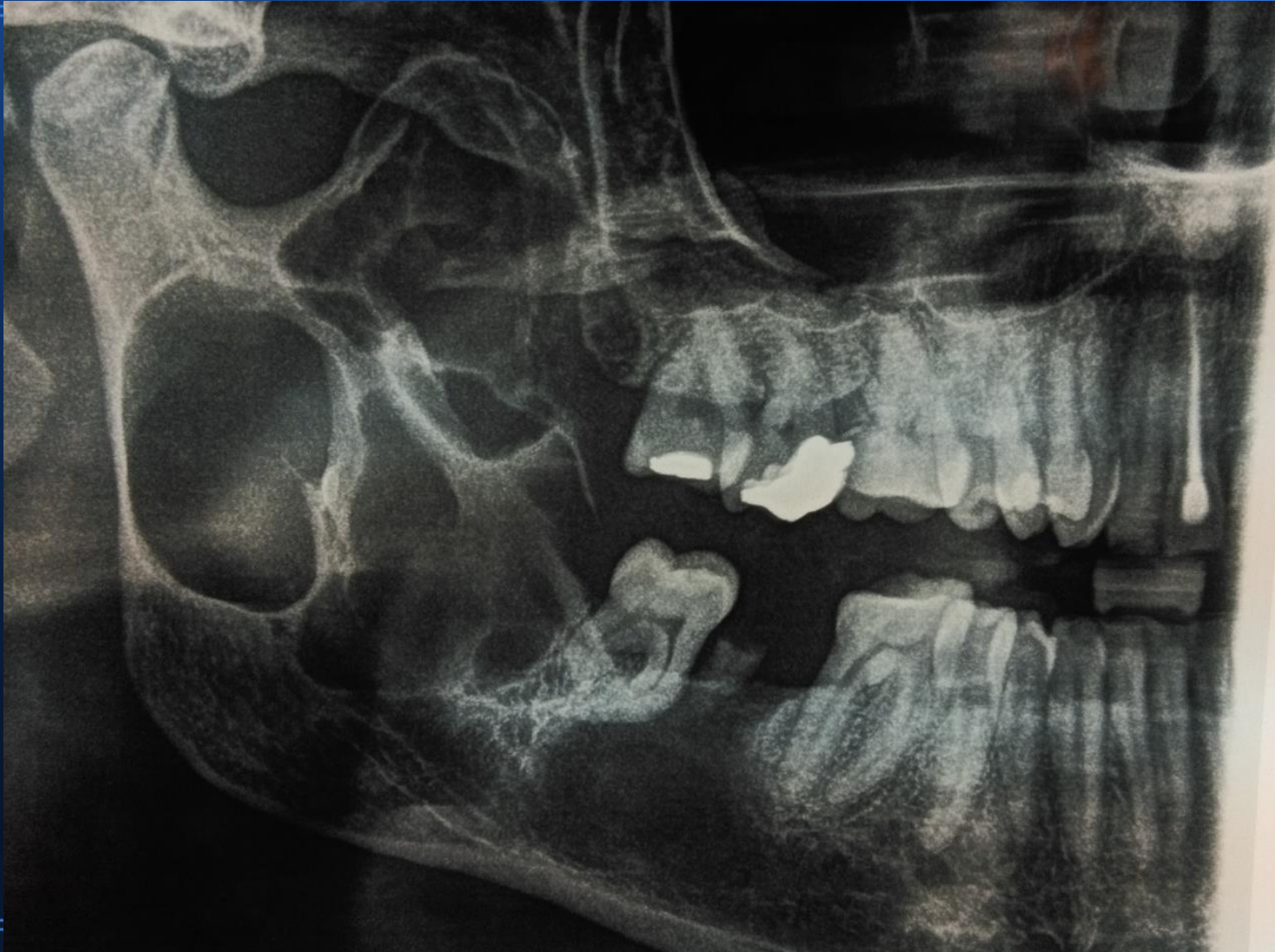
Ameloblastom





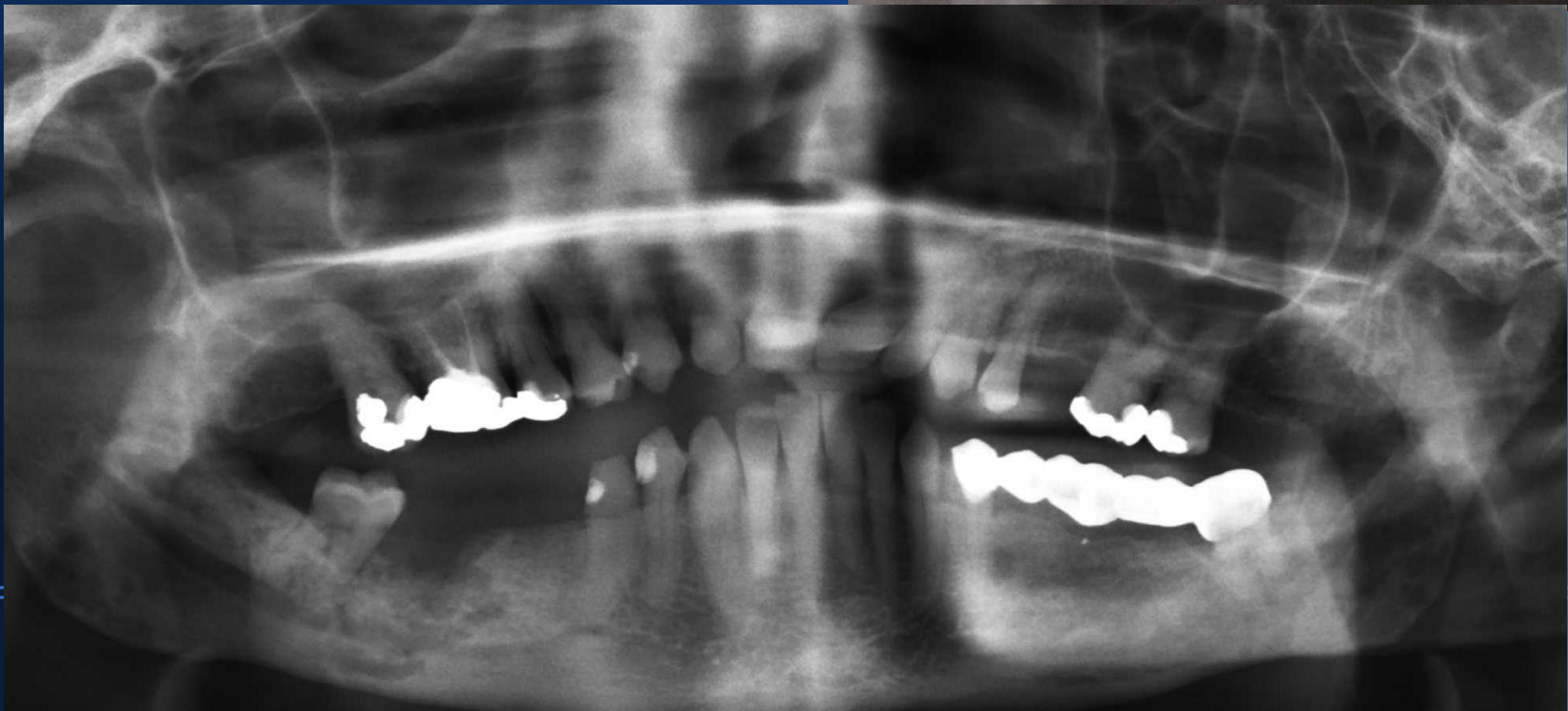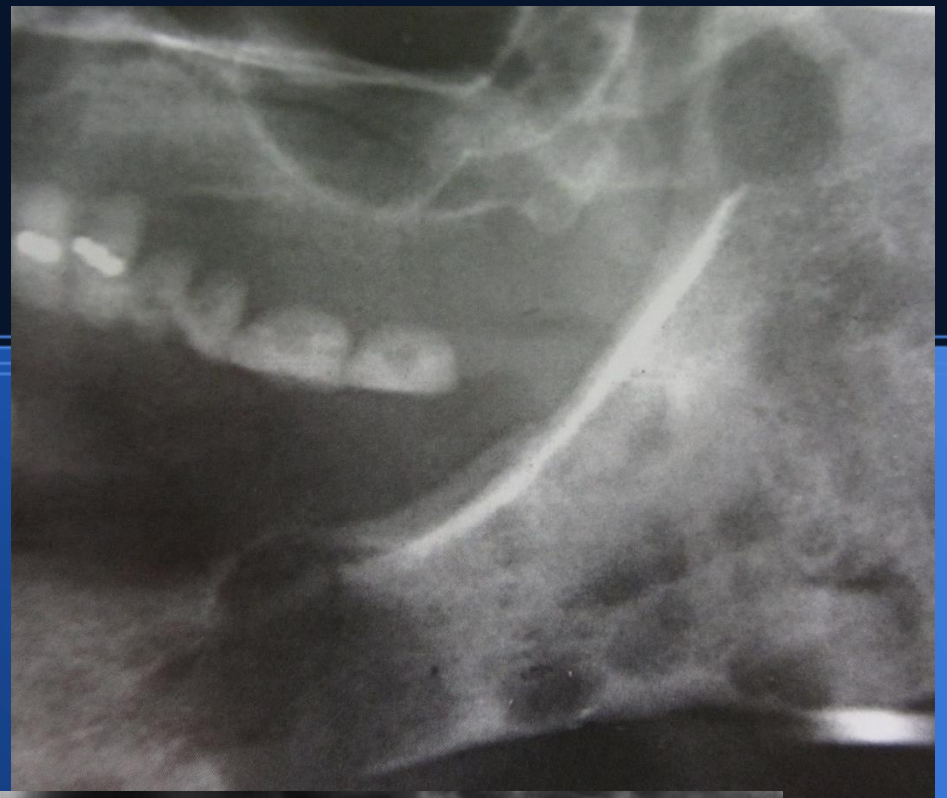
Unicistični ameloblastom u maksili

Keratocista

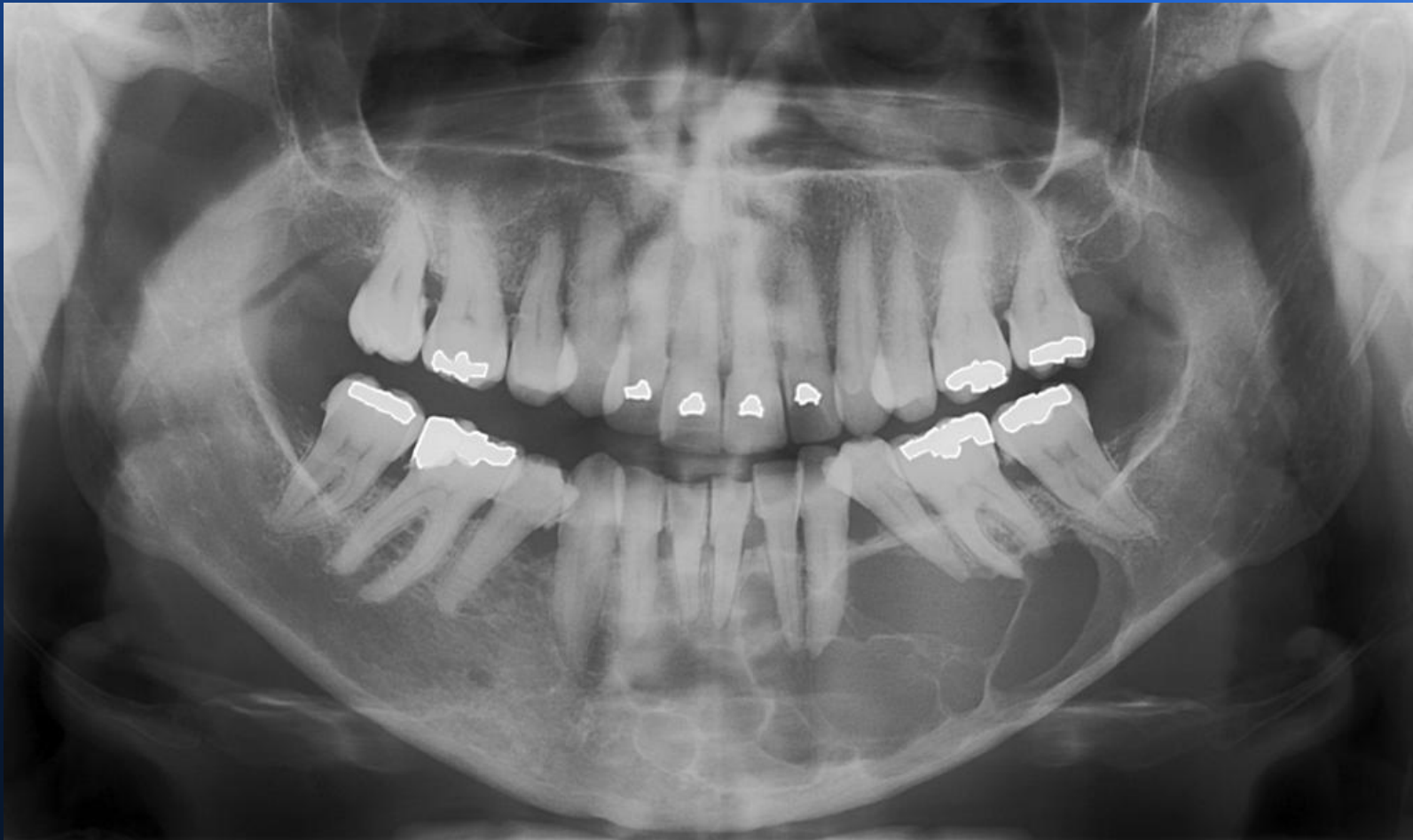


Multipli mijelom-karakteristični

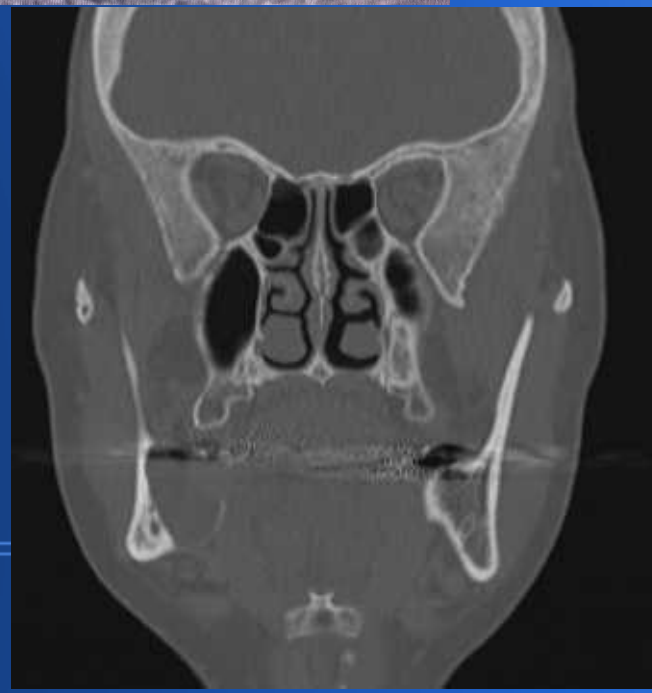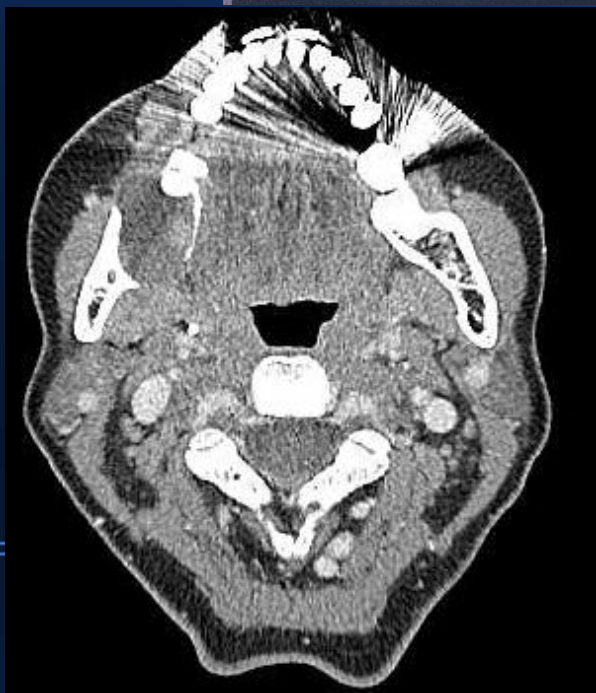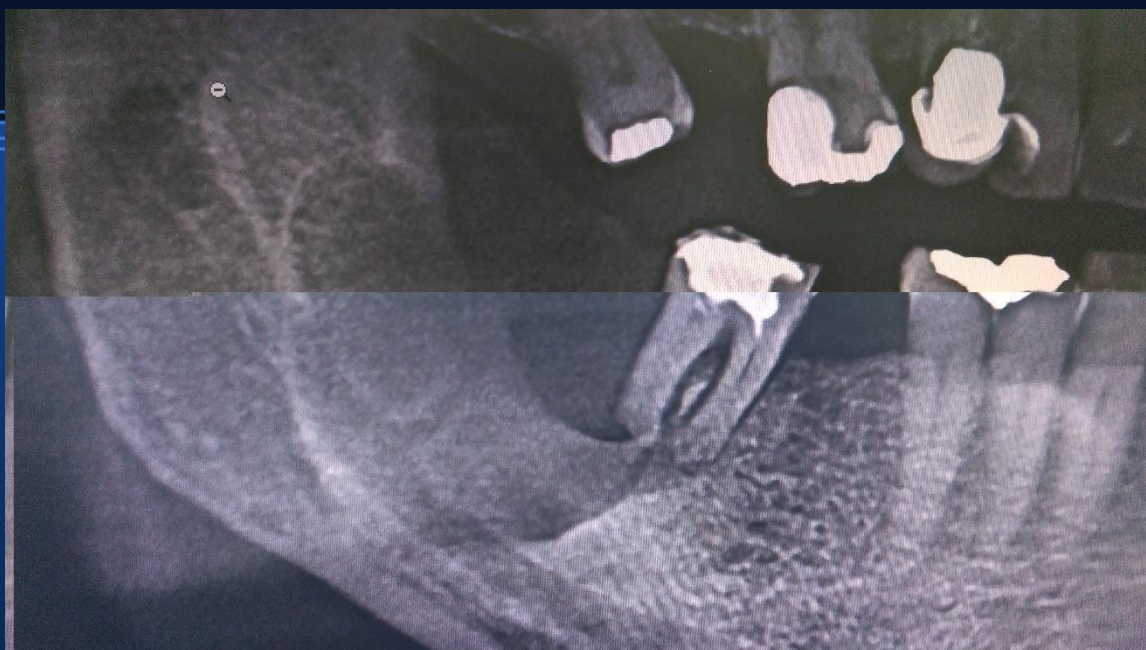
punched out prikaz



Glandularna odontogena cista

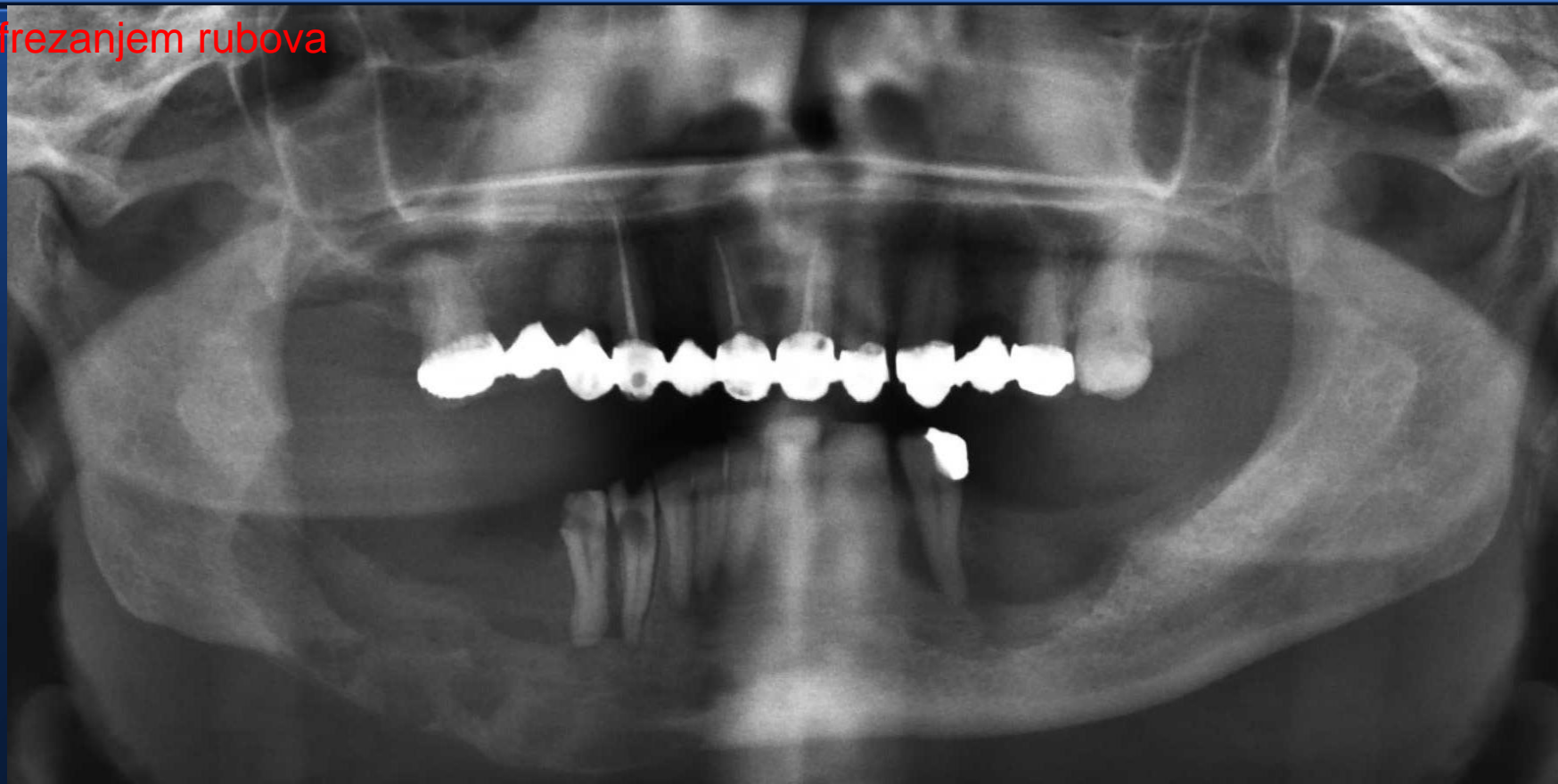


Mukoepidermoidni karcinom

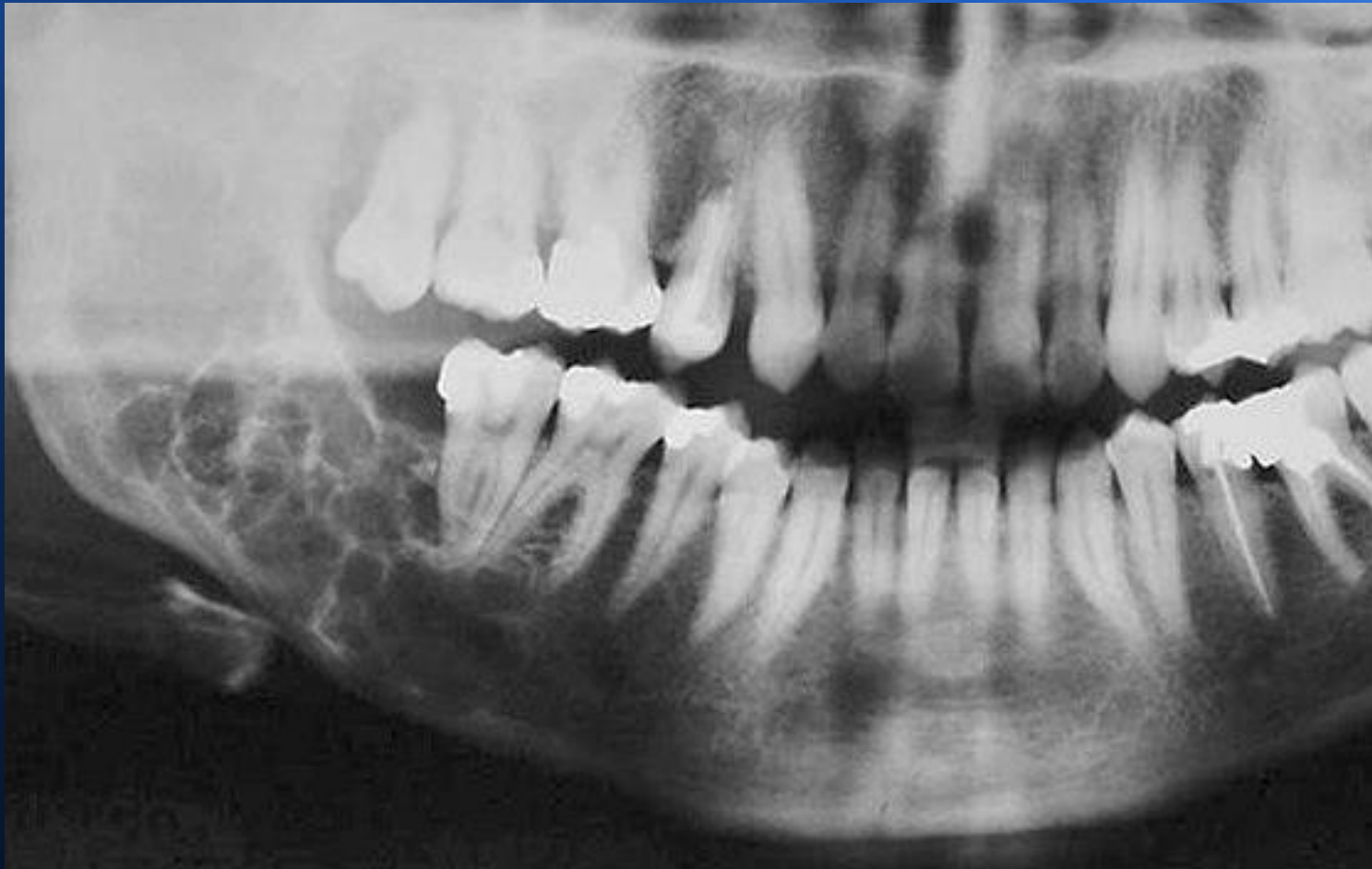

Histiocitoza-obostrano u
mandibuli, desno liječeno iradijacijom,
lijevo kirurški enukleacijom i dodatnim

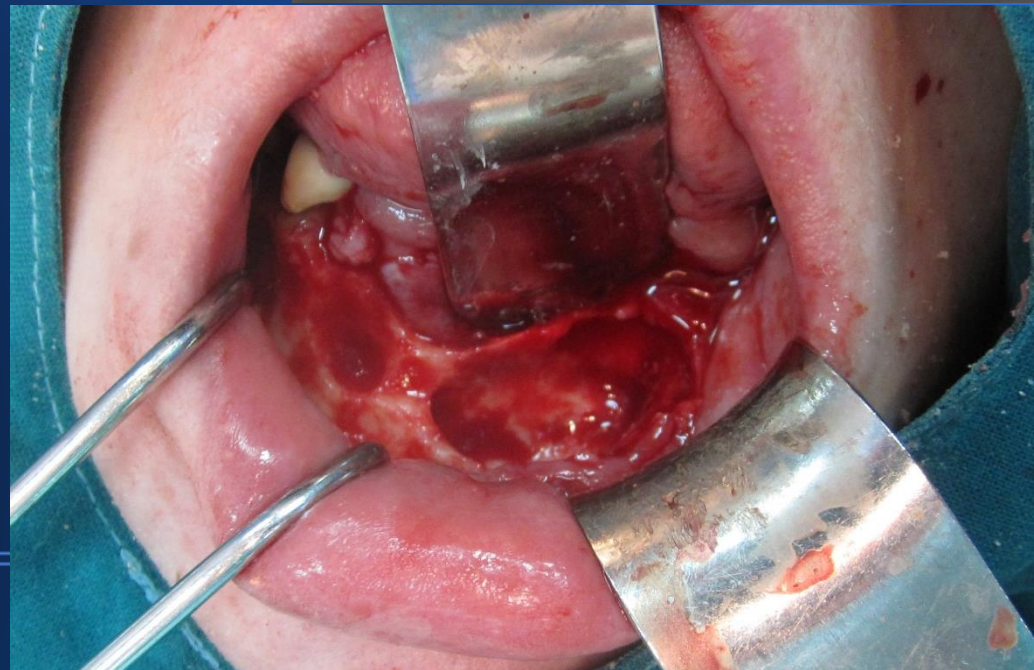
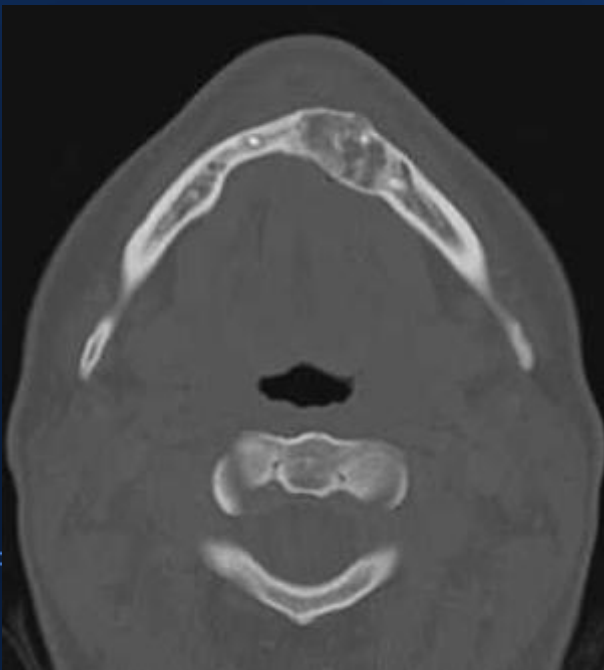
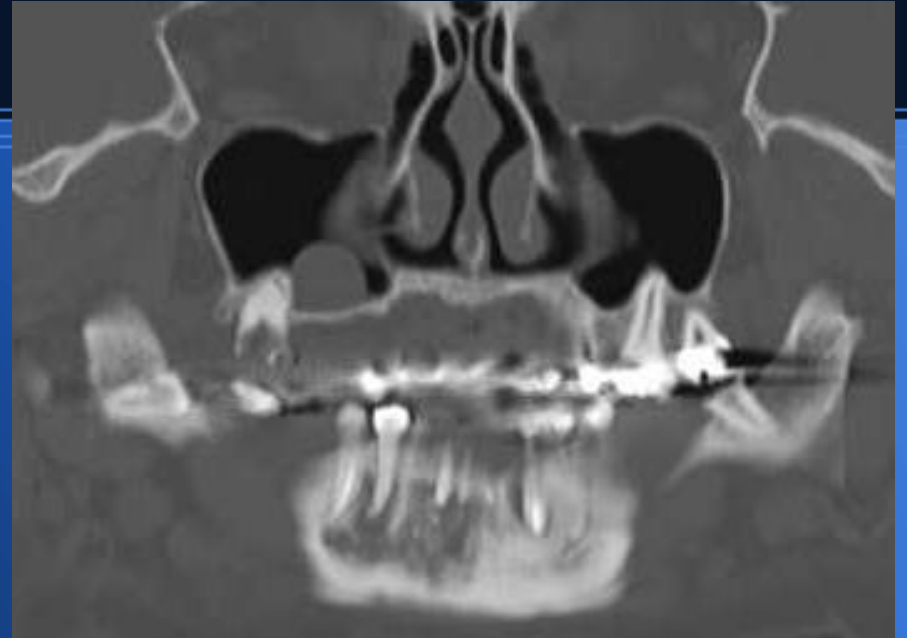
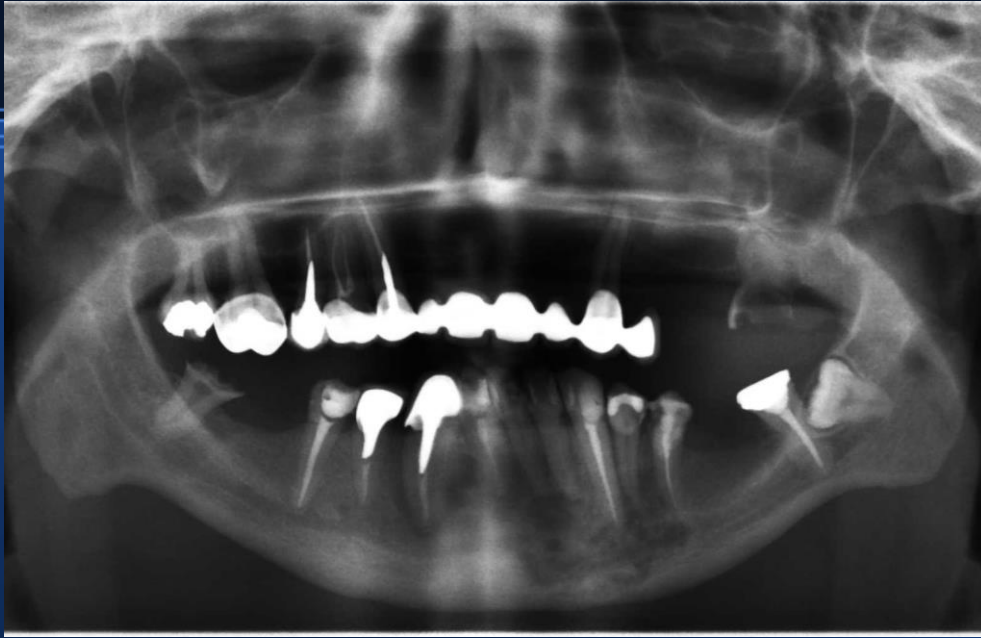frezanjem rubova



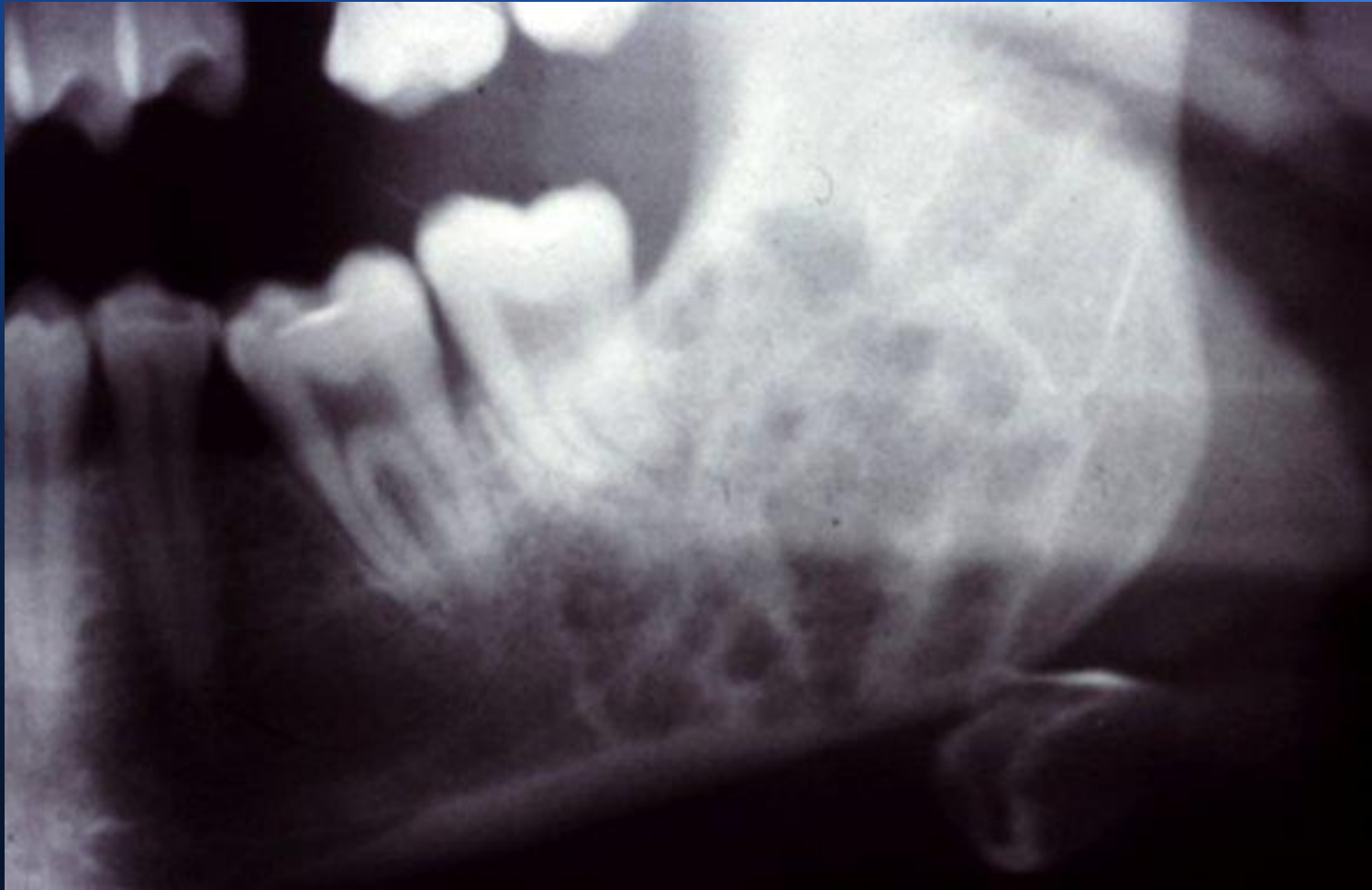Odontogeni miksom



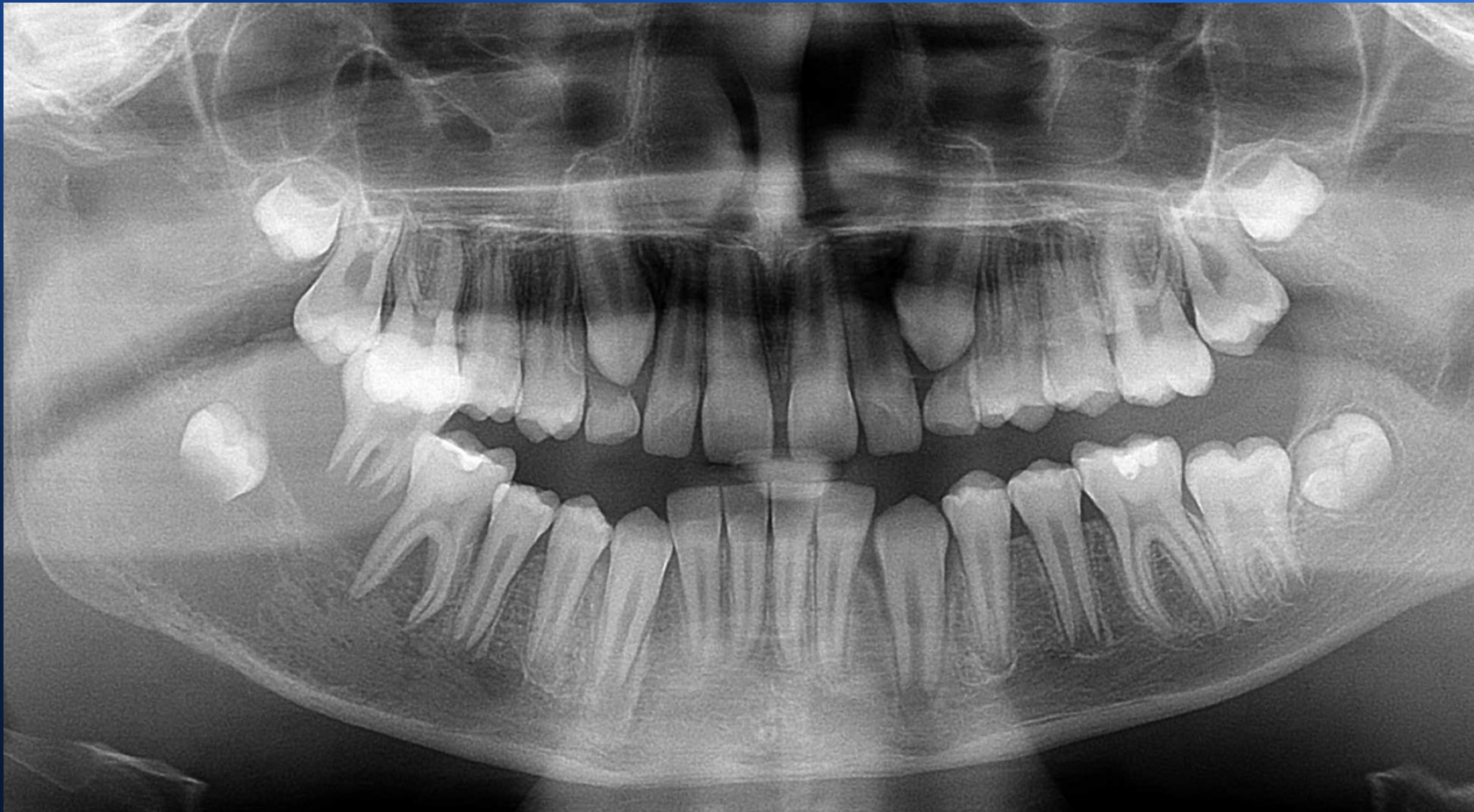
Osificirajući fibrom-mješoviti prikaz prozračnosti i sjene (mineralizacije)



Hemangiom-NIKADA NE VADITI ZUB! Najprije
MSCT angiografija.

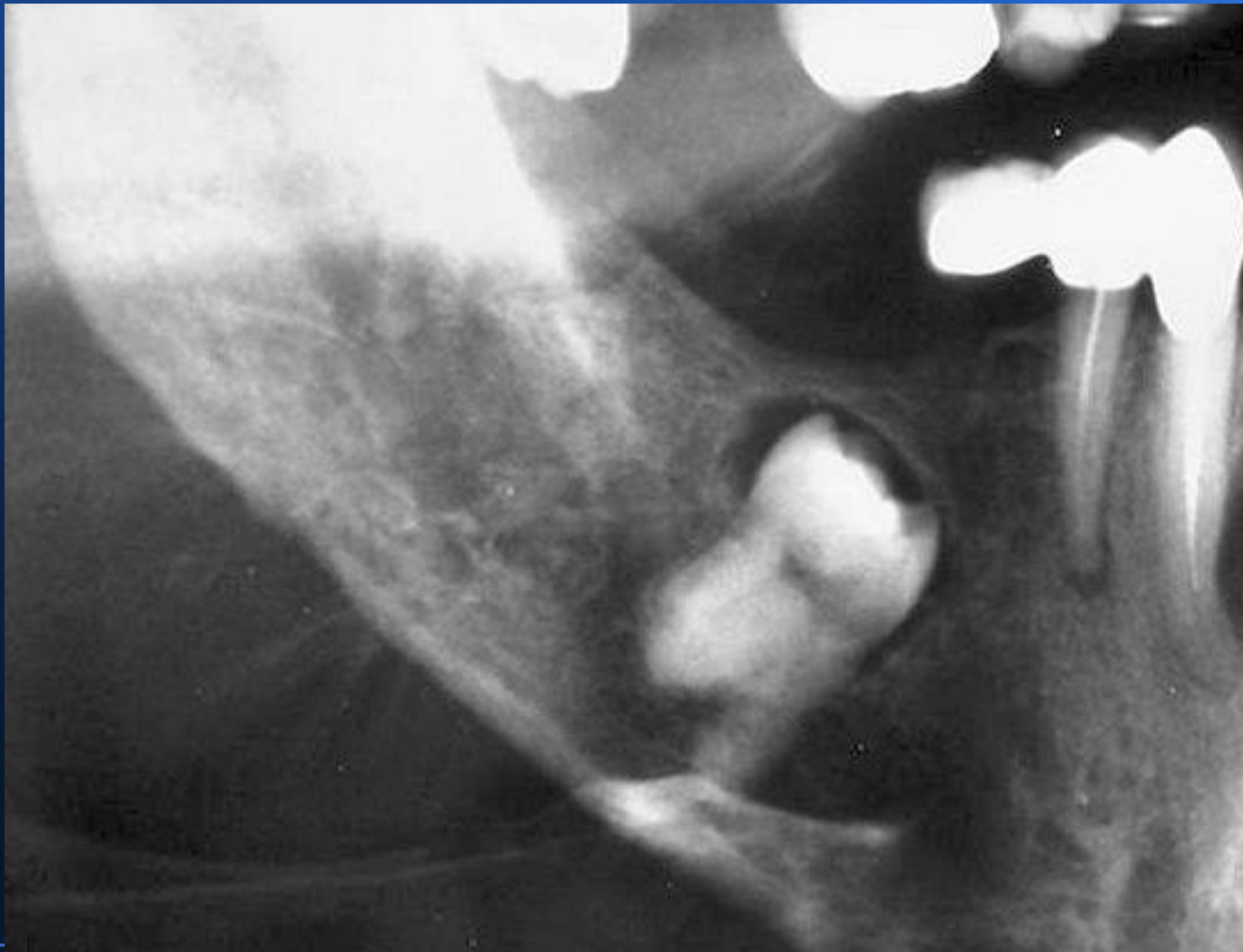

Maligni tumori



Nepravilna transparentcija dolje desno, odignuti zdravi drugi molar. Klinički u ustima egzofitična crvenkasto-plavkasta solidna promjena koja brzo raste!

Osteosarkom-karakterične spikule i nepravilna transparenција



Srdačan pozdrav!